

# Corneal Ulcers: *Diagnosis and Management*

## **Deepinder K. Dhaliwal, MD, L.Ac**

Professor, University of Pittsburgh School of Medicine

Director, Cornea and External Disease Service

Director, Refractive Surgery Service

Director and Founder, Center for Integrative Eye Care

Associate Director, Campbell Ocular Microbiology Laboratory

Medical Director, Refractive Laser Center,

University of Pittsburgh Medical Center



# Disclosures:

Consultant: Bausch & Lomb, Novabay

Research/Speaker: Imprimis, Oasis, Ocular  
Therapeutix, Sightlife, Staar

Trainer: AMO VISX and Intralase Lasers

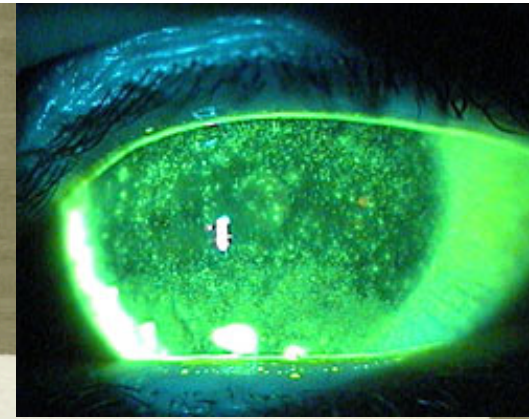
But first...



# 3 Pearls to Rapid Diagnosis of Cornea Patients

# Pearl #1: history-taking

So many symptoms, so little time...



- Never ask open-ended question like “what seems to be the problem”
- Instead, ask “*what are the top 2-3 things that bother you about your eyes*”.
- Also ask “*does anything makes your symptoms better?*”

If patient replies NO:

- Instill artificial tears. If no improvement, try proparacaine. If *still* no improvement → think about neurogenic pain (treat with meds such as gabapentin)

# More important questions

□ Ask "Are symptoms worse in the morning or later in day?"

✓ If **morning**, think:

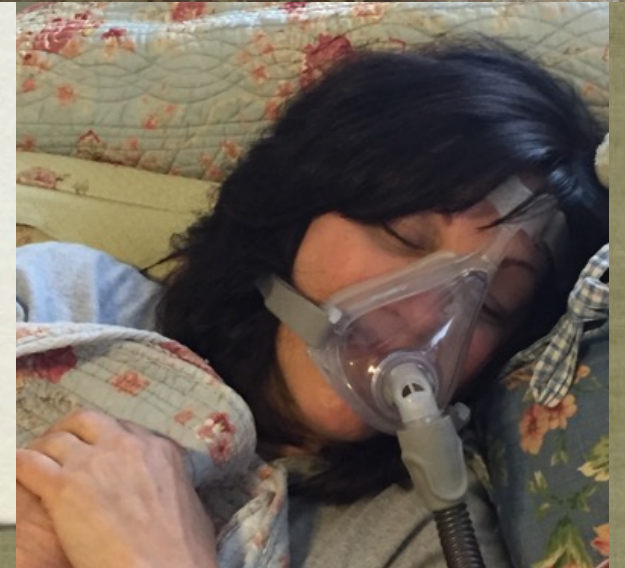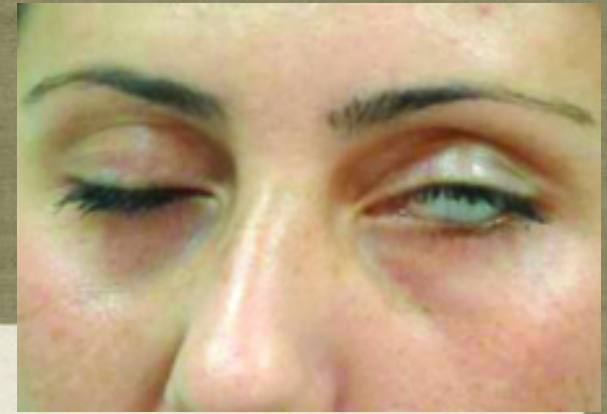- floppy lid
- blepharitis (demodex/staph)
- lagophthalmos

? *Sleep under a fan*

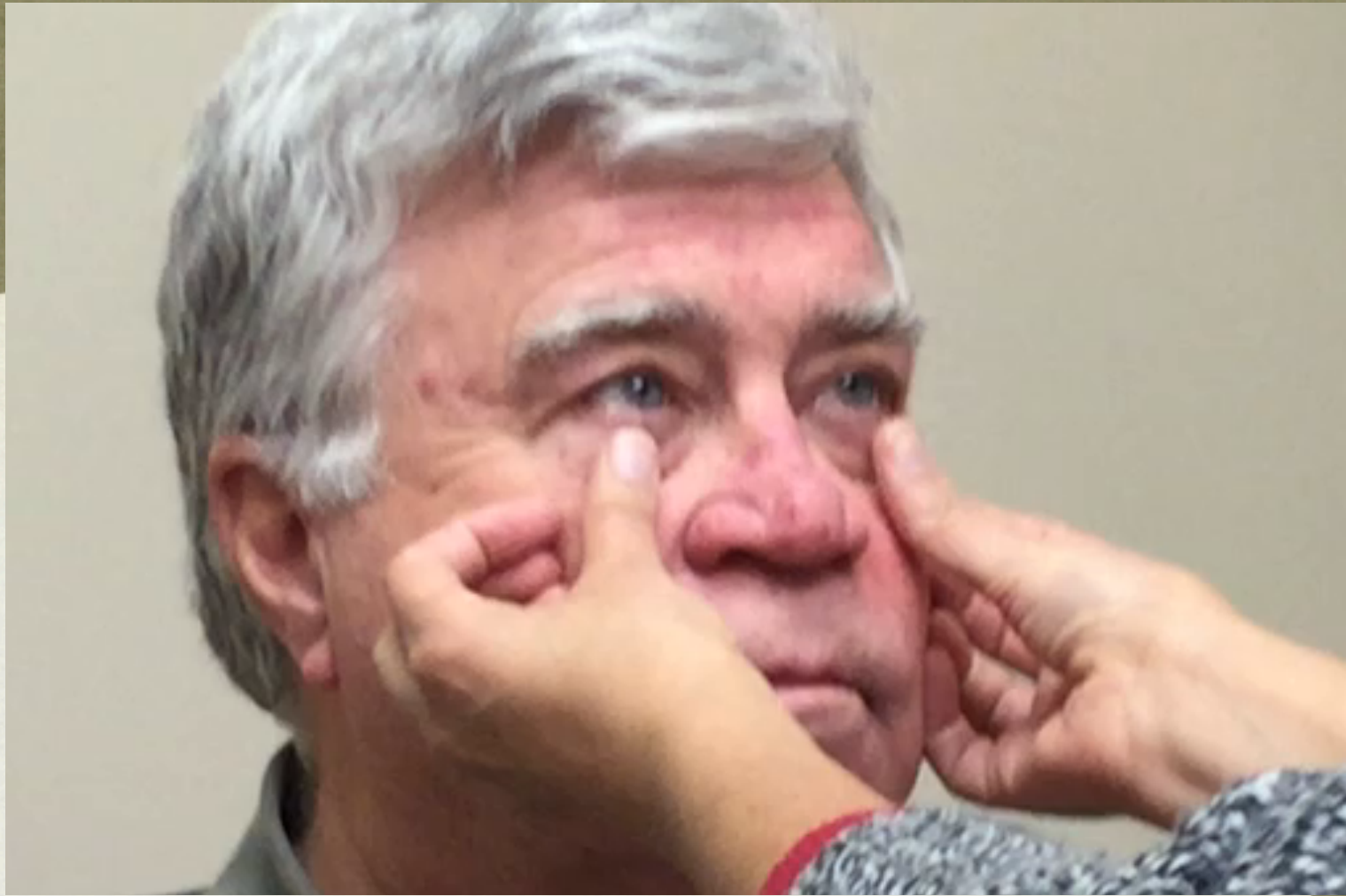? *CPAP machine*

- If so, night goggles helpful!

✓ If **later in day**, think classic "dry eye"

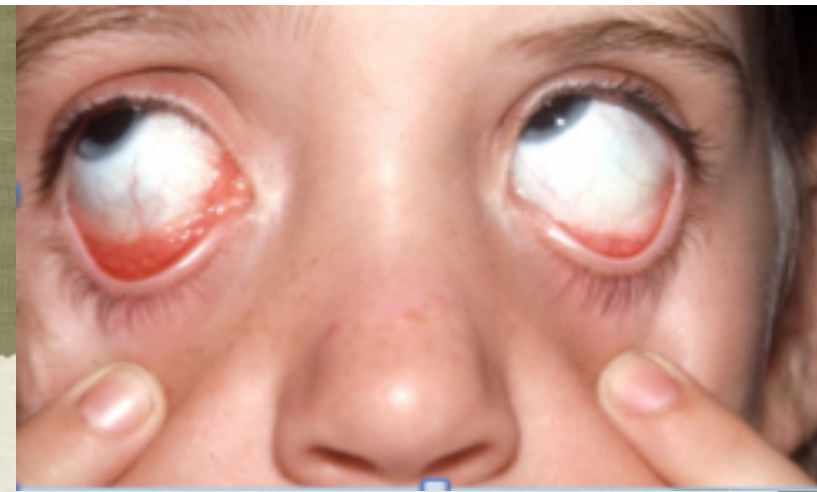

## Pearl #2



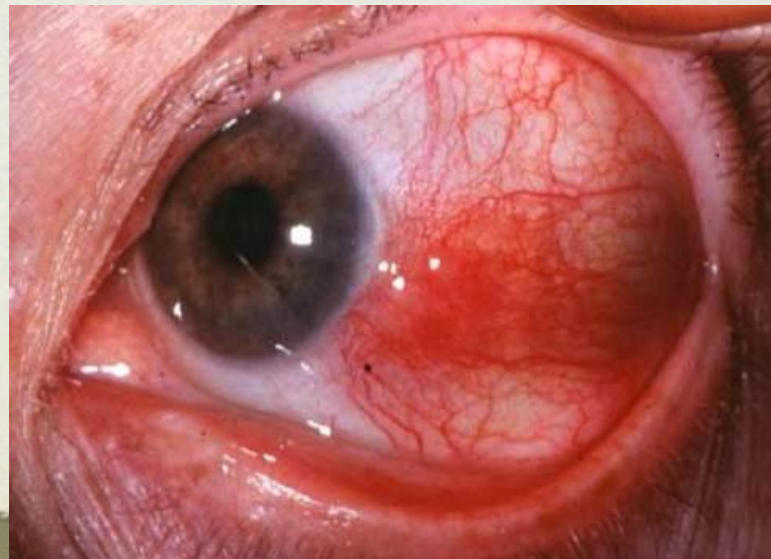- **ALWAYS** do an *external eye exam* (prior to slit lamp exam)
  - Pattern of hyperemia: sectoral vs diffuse vs limbal
  - Perilimbal → think iritis

# External Eye Exam



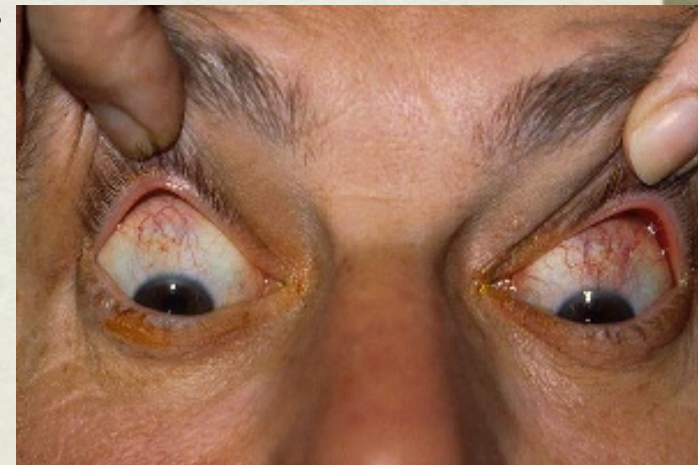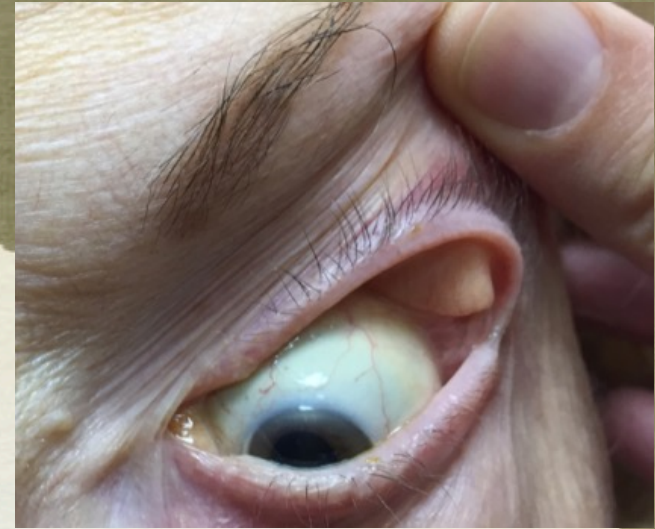## □ EXAM

- ***Pull lower lids down***, have pt look up
  - If hyperemia is involving bulbar *and* tarsal conj, **diagnosis is conjunctivitis.**
  - Hyperemia limited to bulbar conj? Think episcleritis or scleritis



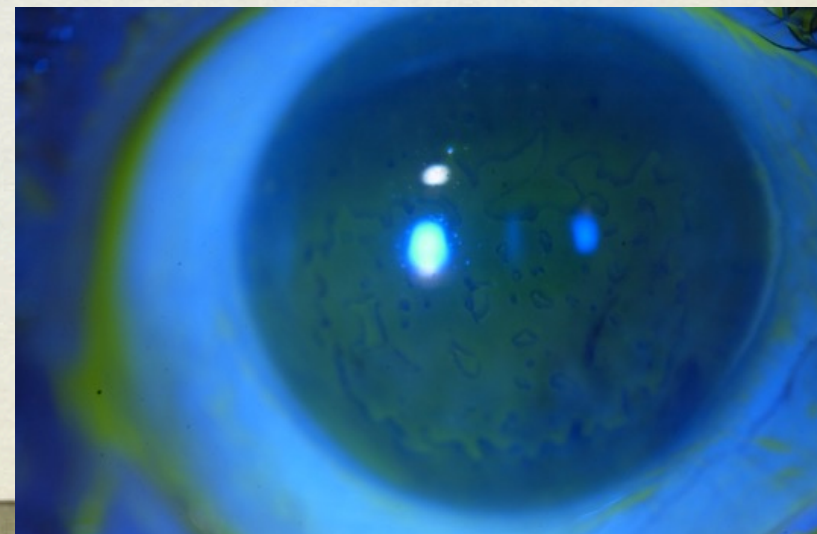
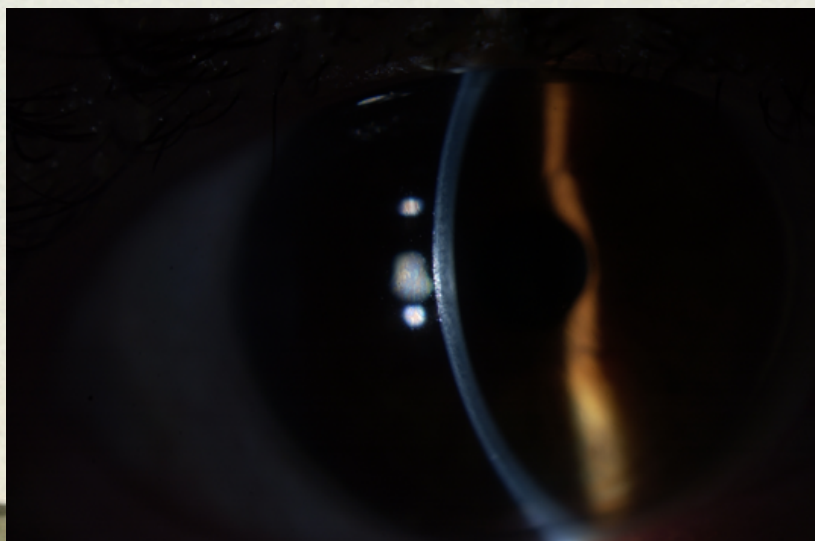
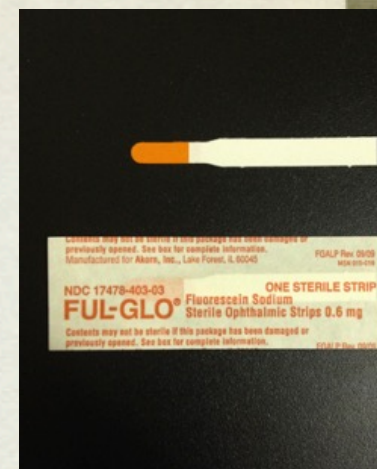***Pull upper lids up***, have patient look down

- ✓ **Floppy lid syndrome**: upper lids evert at night causing irritation in the morning
  - Treatment: wear eye protection at night, lid tightening
  - *Associated with keratoconus and sleep apnea*
- ✓ **SLK (superior limbic keratoconjunctivitis)**: mechanical friction of superior conj with upper lid
  - ✓ Treatment: aggressive dry eye therapy, conj cautery
  - ✓ Associated with thyroid disease, k. sicca



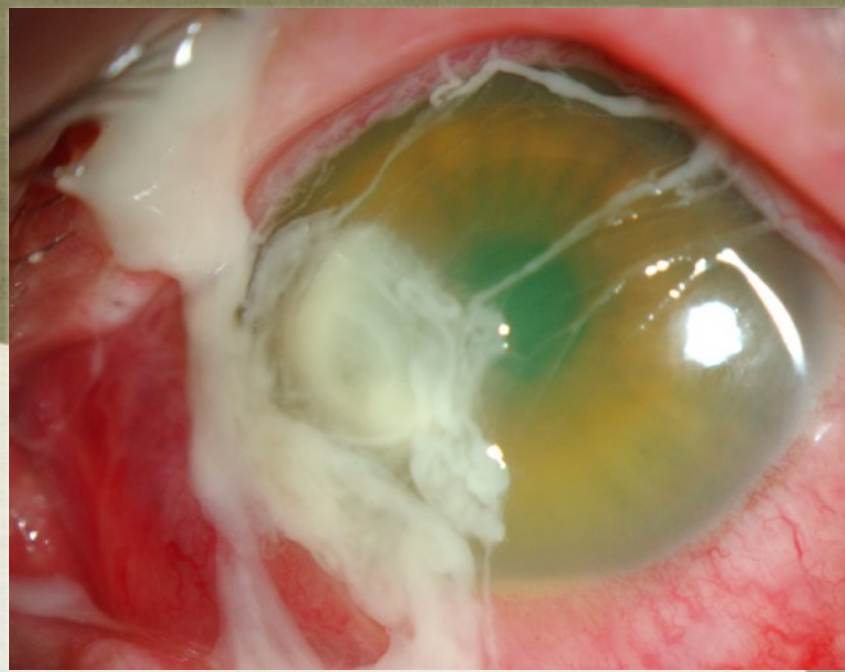
# Pearl #3: To detect subtle corneal changes, use fluorescein strip (NOT Fluress) and diffuse blue light

- ✓ Rule out EMBD in all pre-op cataract and LASIK patients
- ✓ Causes central irregular astigmatism and altered K's
- ✓ LASIK: increased epithelial defects which leads to higher risk of epithelial ingrowth



# CORNEAL ULCERS

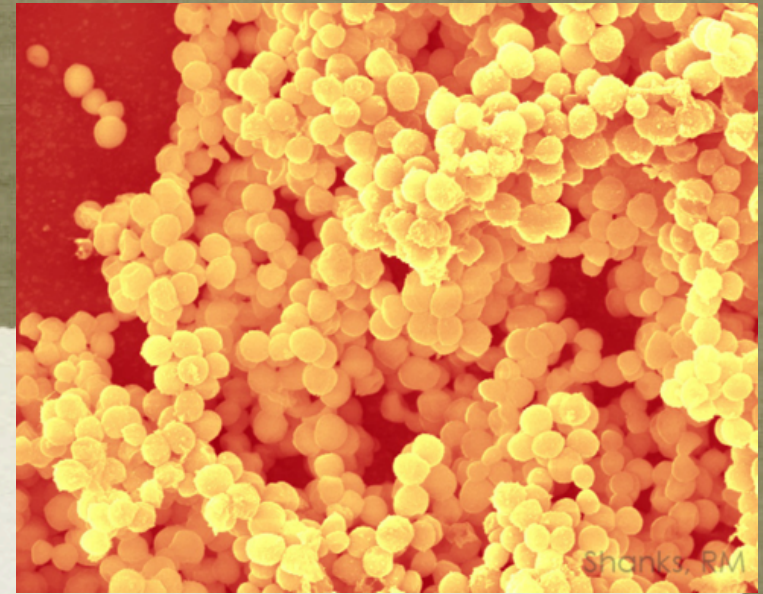
# Infectious Keratitis



- Can be challenging to treat
- If the corneal ulcer is not responding to initial therapy after 2-3 days, must reassess
- Simple question to ask patient every visit: “do you feel better, the same, or worse”
- Clinical exam may lag actual improvement

# Infectious Keratitis

- **Poor response** can be due to:
  - Wrong diagnosis
  - Wrong treatment
  - Right treatment, but “wrong” patient (poor compliance)
  - Other factors: poor penetration/biofilm



*Staph aureus* biofilm

Courtesy: Rob Shanks, PhD

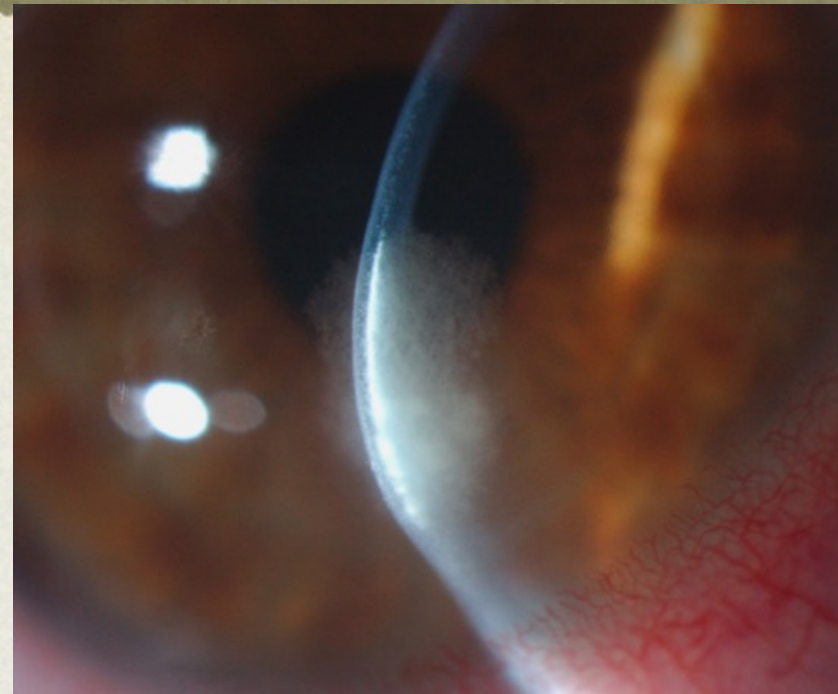
# CORRECT DIAGNOSIS



- Important to understand WHY the patient has an ulcer
  - Contact lens wear, rosacea, exposure, trichiasis, neurotrophic
- ***Time is of the essence***--delay in diagnosis or proper treatment could make the difference between a successful outcome and a perforated cornea needing an emergency corneal transplant
- *Infiltrate may be subtle* (especially if patient on steroid therapy or immunocompromised)
- *Epithelial defect may not be present*

# Infectious keratitis: etiology

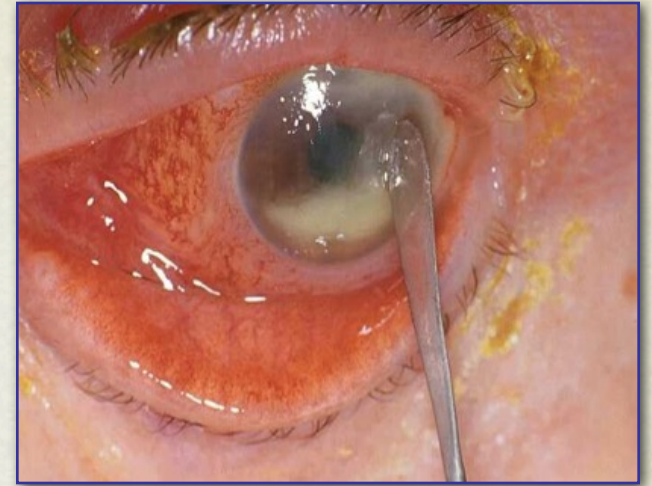- Bacteria
- Fungus--*candida*, *fusarium*
- Acanthamoeba
- Virus--HSV
- Non-tuberculous mycobacterium



# Keratitis: When to Culture/Scrape

## **No need** to culture:

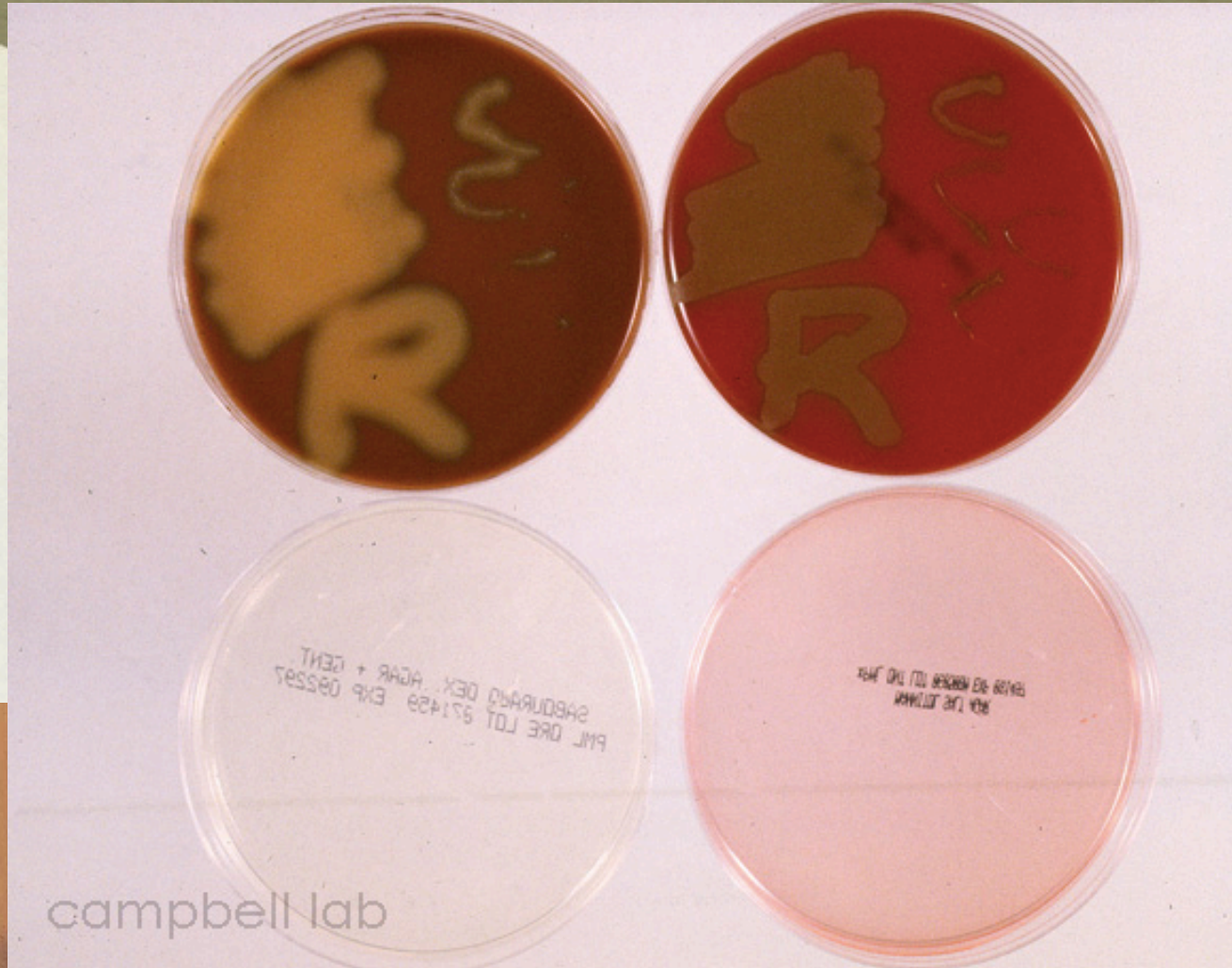
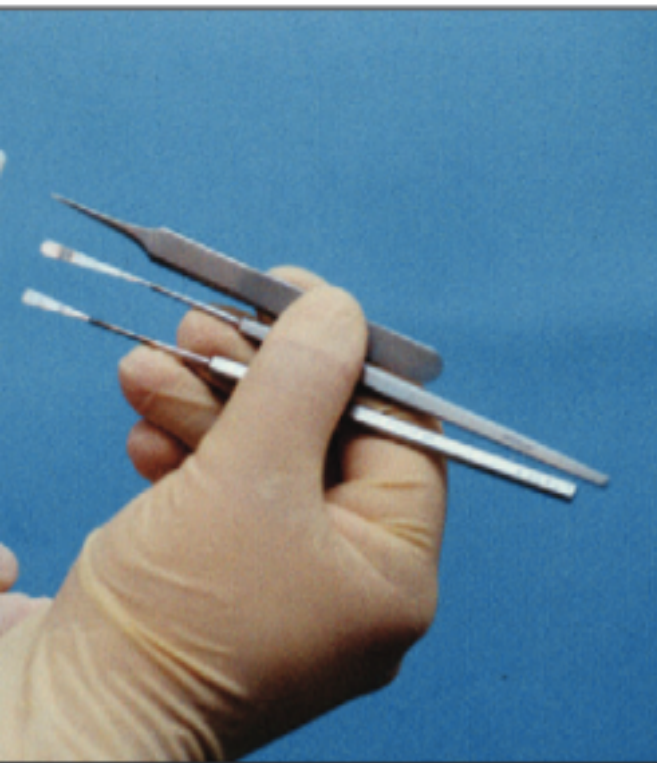
- Small (1-2mm)
- Peripheral



## Cultures **recommended**:

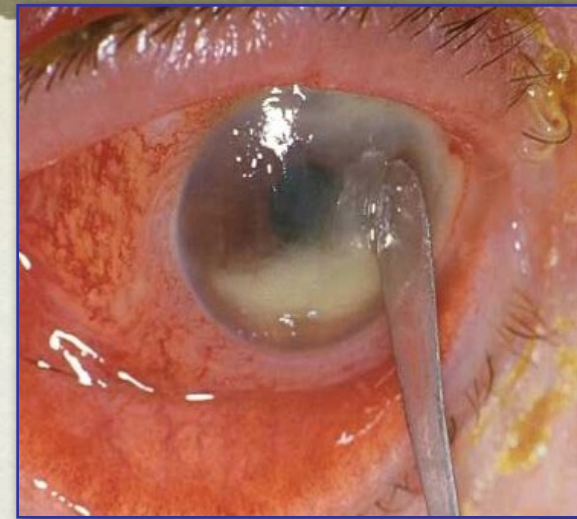
- Large (>2mm), extends to mid, deep stroma, Central, vision threatening
- **Post surgical (refractive surgery)**—remember to LIFT flap if infection sequestered under flap
- Suspicious history or clinical course
- Poor response to initial treatment

# Culture, Perform Scrapings, PCR



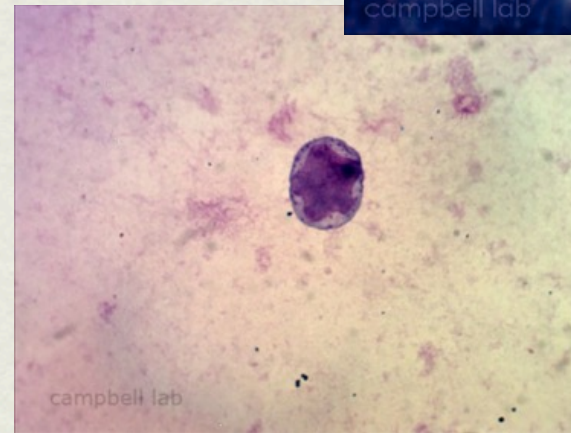
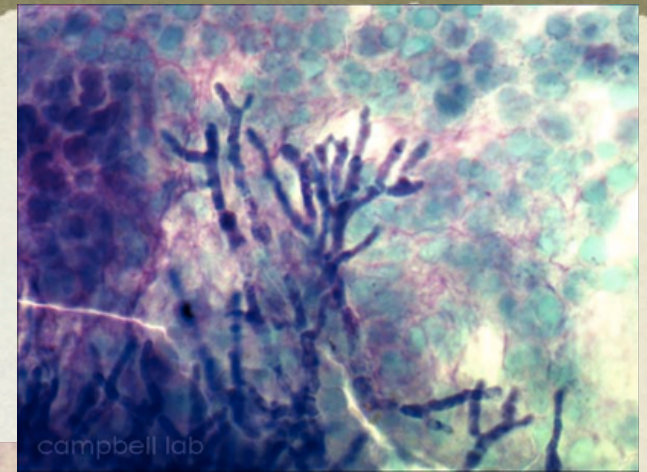
# Culture and Scraping PEARLS

- Get specimen from leading EDGE
  - *Avoid necrotic center*
  - *Debride as much as possible*
- Don't be shy--get adequate specimen
- Don't use cover slip on slides
- Culture CL case and solution
- Debride as much as possible--can be curative



# Think of Atypical Organisms if not responding to initial therapy

- Non-tuberculous mycobacteria
  - ✓ will grow on blood agar
- Fungus
- Acanthamoeba--PCR
- Nocardia
- HSV--PCR
- IF CULTURE NEGATIVE, consider confocal microscopy or corneal biopsy



**CORRECT TREATMENT**

**[www.eyemicrobiology.upmc.com](http://www.eyemicrobiology.upmc.com)**

**Susceptibility\* of Bacterial Isolates from Keratitis to Common Antibiotics  
(Percent Susceptible)(1993 to January 1, 2015)**

<b>Bacteria</b>	<b>#</b>	<b>BAC</b>	<b>VAN</b>	<b>GEN</b>	<b>CIP</b>	<b>OFX</b>	<b>PB</b>	<b>CEF</b>	<b>TOB</b>	<b>SULF</b>	<b>METH</b>	<b>GAT</b>	<b>MOX</b>
<b>Staphylococcus aureus</b>	476	93	100	93	68	68	1	88	75	97	60	68 (222)	73 (222)
<b>Coag-Neg Staphylococcus</b>	165	90	100	76	46	46	35	92	72	87	34	69 (74)	69 (74)
<b>Streptococcus pneumoniae</b>	100	100	100	10	98	98	4	100	2	96	--	100 (50)	100 (50)
<b>Streptococcus viridans</b>	120	99	100	50	69	87	3	99	26	97	--	90 (48)	94 (48)
<b>Other Gram-Positives</b>	112	77	97	68	68	68	50	77	56	51	--	69 (51)	67 (51)
<b>Pseudomonas aeruginosa</b>	312	0	0	97	97	95	100	0	99	7	--	96 (197)	92 (197)
<b>Serratia marcescens</b>	159	0	0	99	99	99	9	0	96	87	--	97 (39)	95 (39)
<b>Moraxella species</b>	75	99	96	99	100	100	99	97	99	99	--	100 (34)	100 (34)
<b>Haemophilus species</b>	46	13	4	85	100	100	96	70	100	67	--	100 (22)	95 (22)
<b>Other Gram-Negatives See Table Below</b>	198	15	9	87	93	92	77	45	87	91	--	89 (85)	88 (85)
<b>Gram-Neg (Contact Lens) See Table Below</b>	327	9	13	61	92	89	78	16	59	77	--	91 (197)	87 (197)

**\* Disk diffusion susceptibilities based on NCCLS serum standards.**

BAC=Bacitracin; VAN=Vancomycin; GEN=Gentamicin; CIP=Ciprofloxacin; OFX=Ofloxacin; PB=Polymyxin B; CEF=Cefazolin; TOB=Tobramycin; SULF=Sulfasoxazole; METH=Methicillin; GAT=Gatifloxacin; MOX=Moxifloxacin; (--)=not done; (#) for GAT and MOX= # isolates tested.

# Treatment PEARLS



- Switch to fortified antibiotics if patient was on monotherapy
- Use most potent agent
- Cidal agents preferred over static
- Not all agents have equal corneal penetration
- Biofilm can modify antimicrobial effect
- Cover MRSA in health care workers
- “Doom and gloom” speech

# Corneal ulcer: Treatment

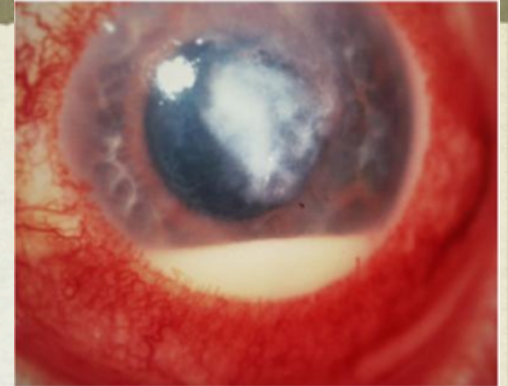
## Fluoroquinolone monotherapy

- Dosing and compliance are critical!!!
- Our Loading Regimen:
  - ✓ Every 5 min for 5 doses
  - ✓ Every 15 min for 5 doses
  - ✓ Every 30 min until 11pm
- Then hourly around the clock
- NEVER use steroids initially



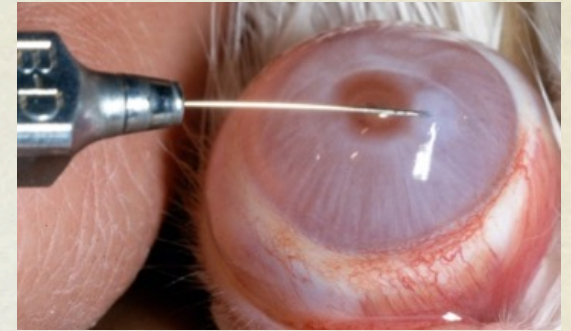
# Corneal ulcer: Treatment

- **Fortified antibiotics**
  - Tobramycin 14mg/ml **PLUS**
  - Cefazolin 50mg/ml **OR**
  - Vancomycin 25mg/ml (esp if MRSA)
- Instruct patient to use drops hourly around the clock (wait 5 minutes in between drops).
- *Doxycycline 50-100 mg po BID (to decrease melting) and Vitamin C 1000mg po BID*
- **NEVER use steroids initially (SCUT trial)**

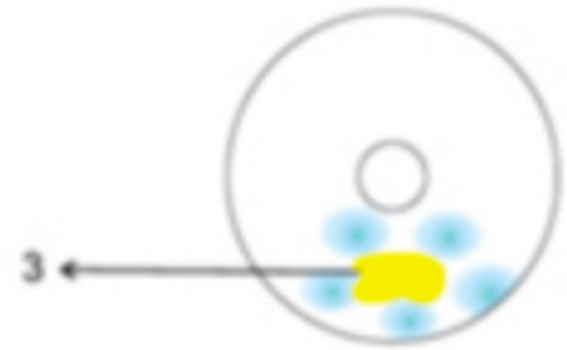
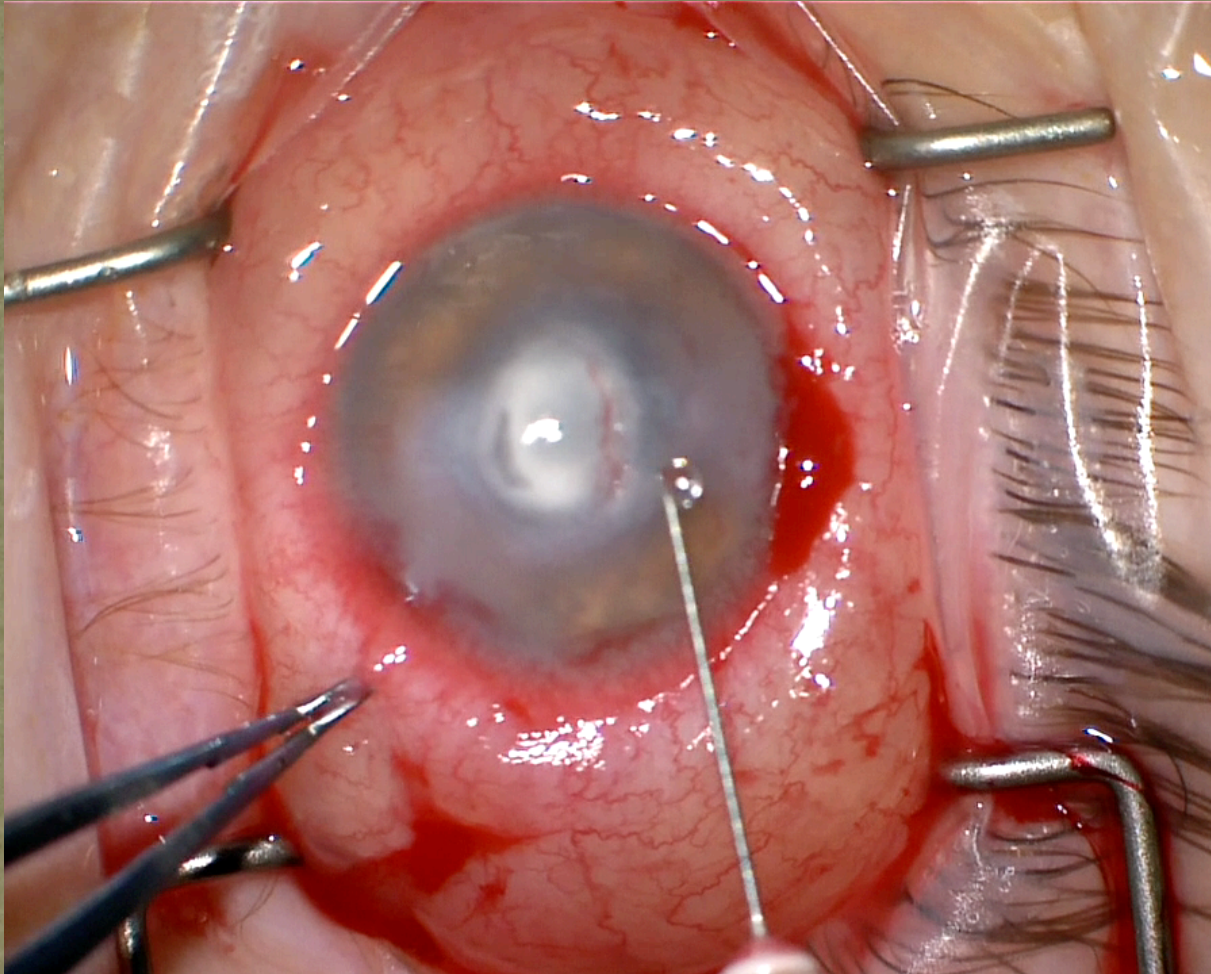


# When topical therapy fails...

- Take compliance out of the equation
- **Intrastromal** injection/soak
- **Intrascleral** injection
- **Intracameral** injection
  - ✓ Voriconazole: 50-100  $\mu\text{g}/0.1\text{ ml}$
  - ✓ Amphotericin B: 5.0-7.5  $\mu\text{g}/0.1\text{ ml}$
  - ✓ Vancomycin: 1 mg/0.1 ml
  - ✓ Amikacin: 400  $\mu\text{g}/0.1\text{ ml}$

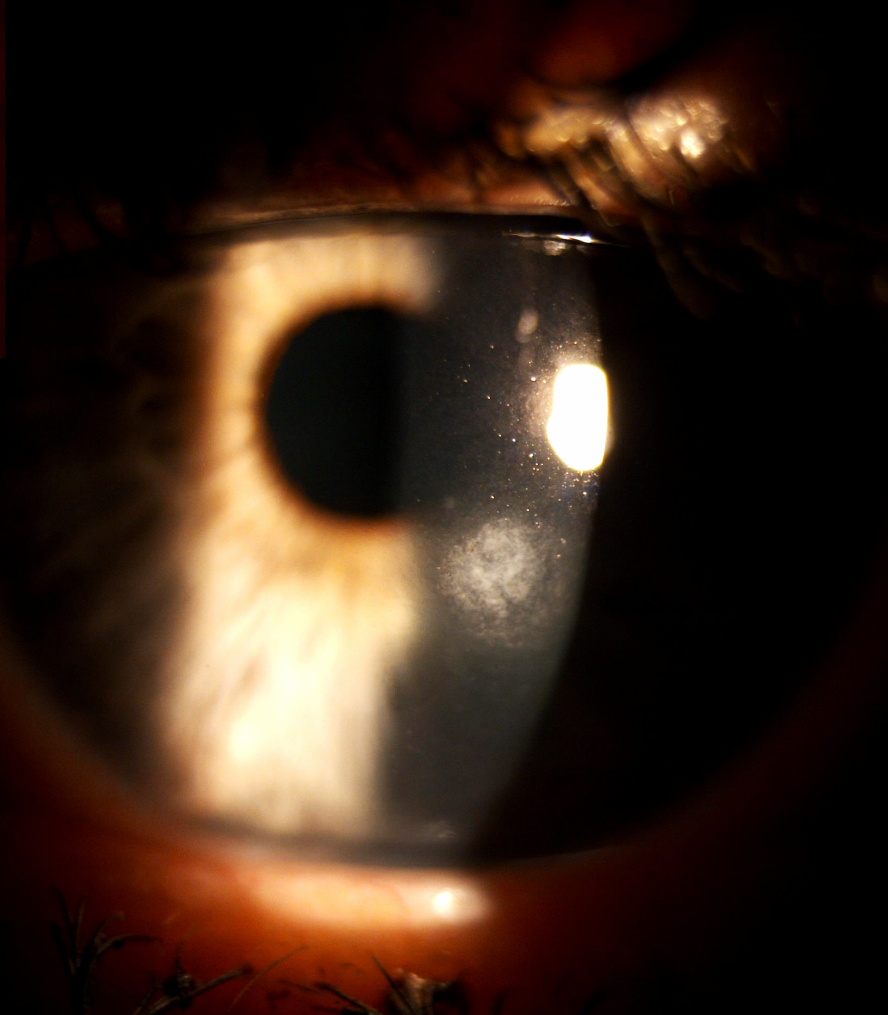
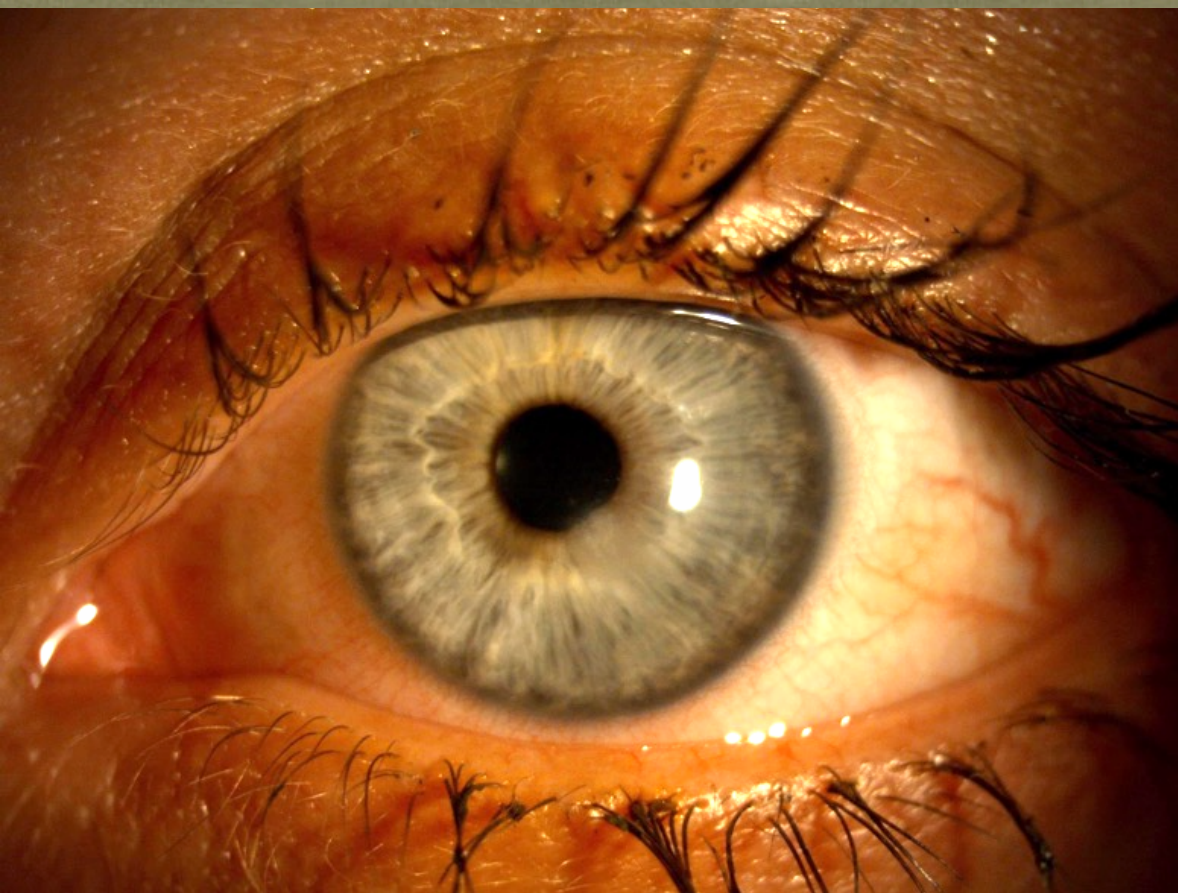

# Intrastromal injection



Del J Ophthalmol - Vol 27 No: 1 July-September 2016

Courtesy of Alex Mammen

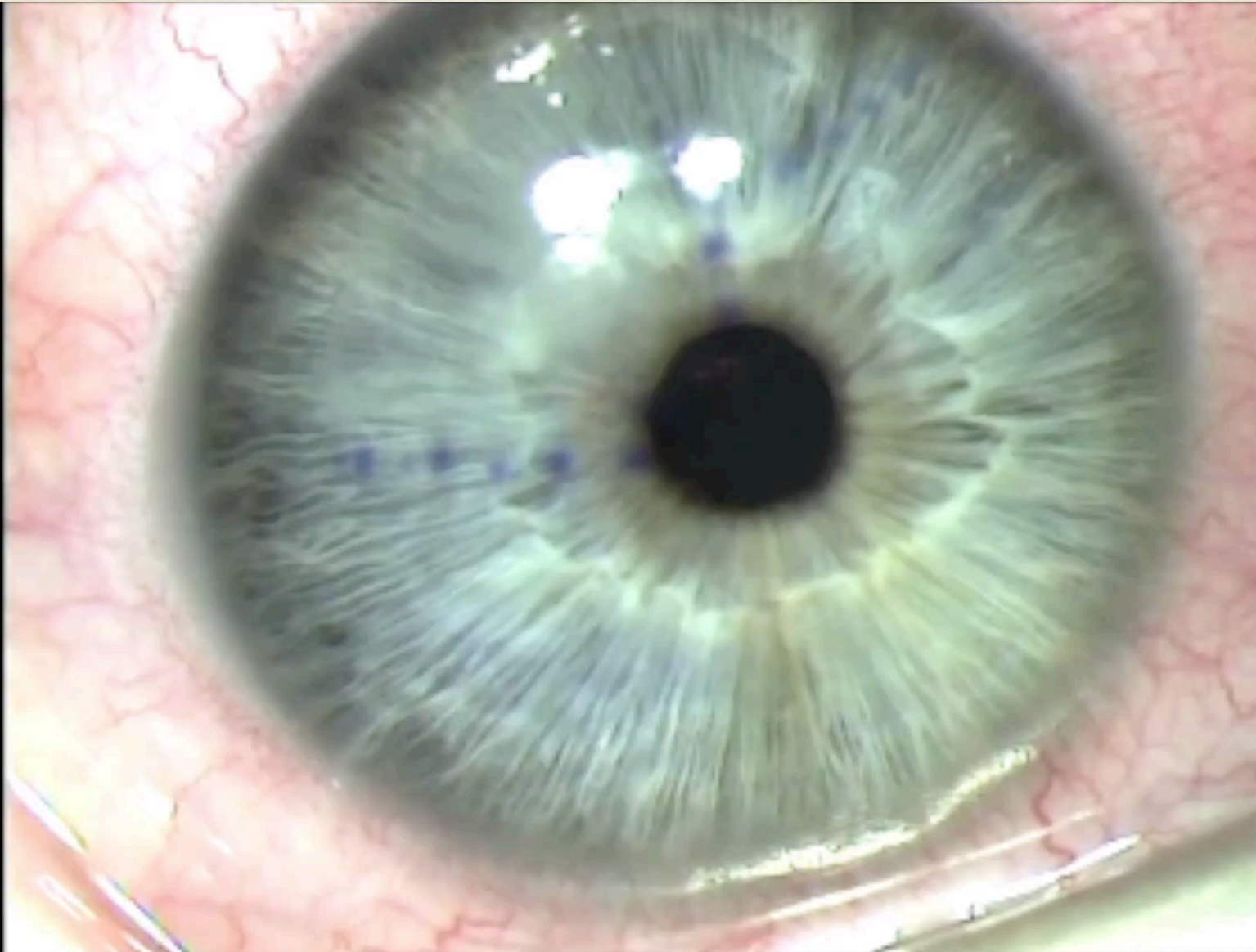


s/p LASIK 10 years ago

OS hit with a banana

Referred to Univ of Pittsburgh  
with white spot

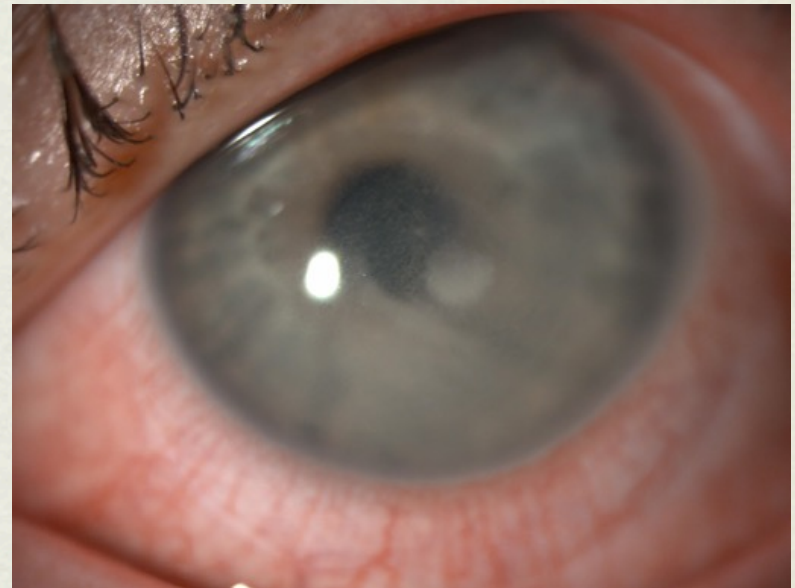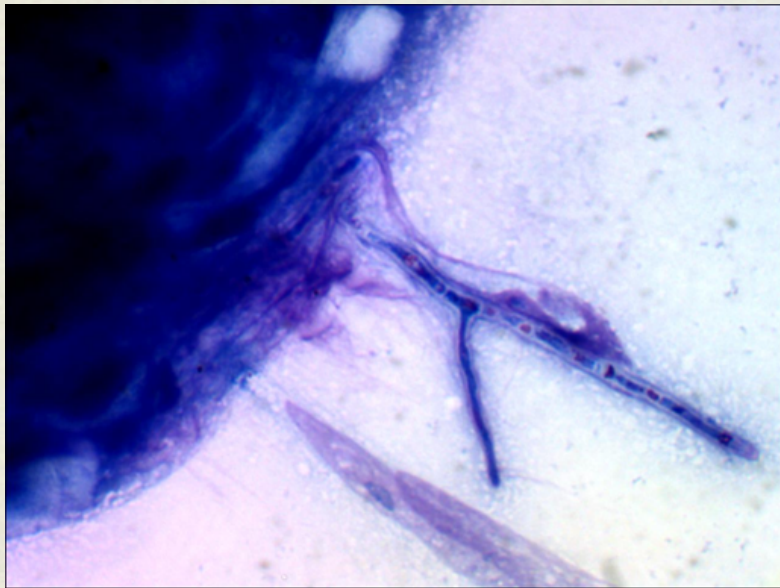
Post LASIK: lift flap if infection  
sequestered under flap



# Microbial Keratitis Post LASIK:

## TREATMENT

- Scraping came back with fungal elements. Patient returned next day with increased pain, redness.

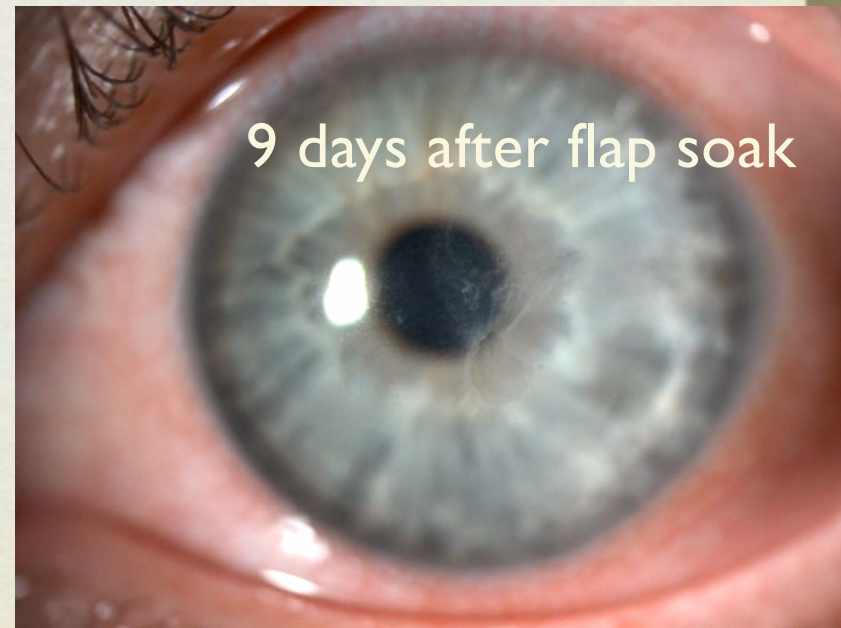
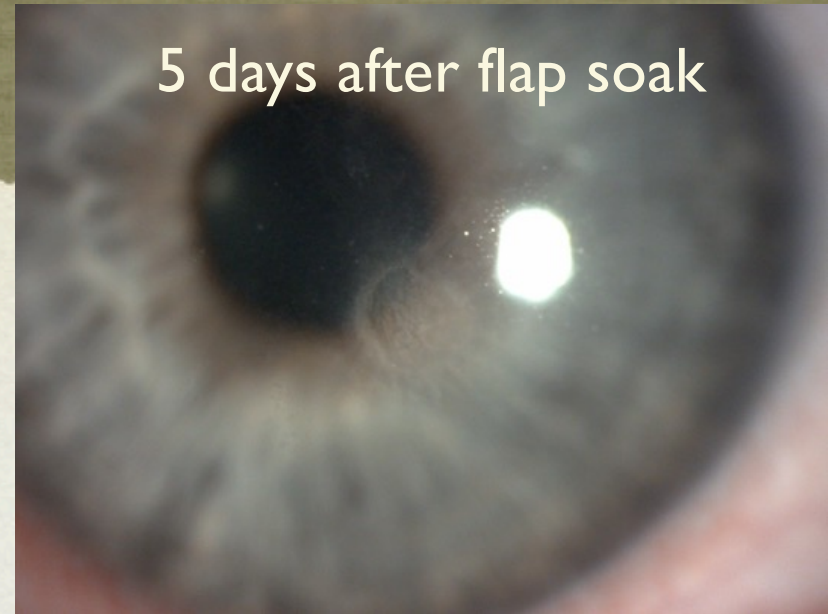

- Next day: **flap soak** (40 min) with voriconazole 100ug/0.1ml and amphotericin B 5.0ug/0.1ml

# Microbial Keratitis Post LASIK:

## TREATMENT

- Pain MUCH improved the day after flap soak!
- Clinical exam improved rapidly
- 9 days later, infection essentially resolved. Flap melted in area of infection. Epithelial ingrowth recurred (removed) and current vision is 20/25

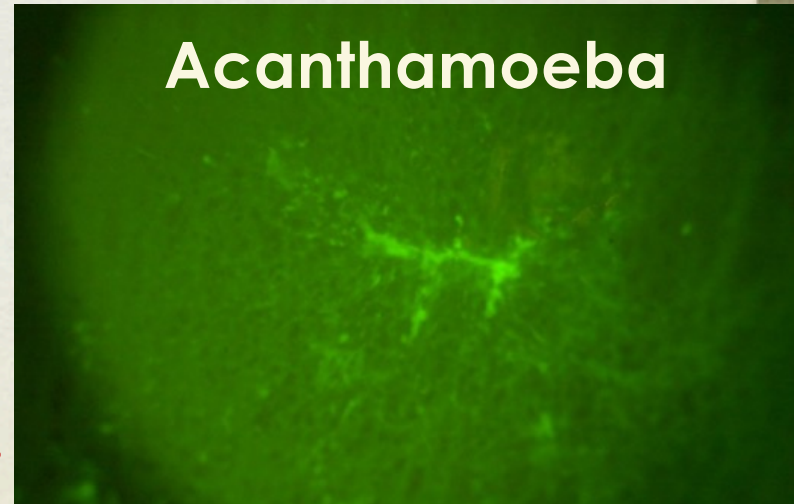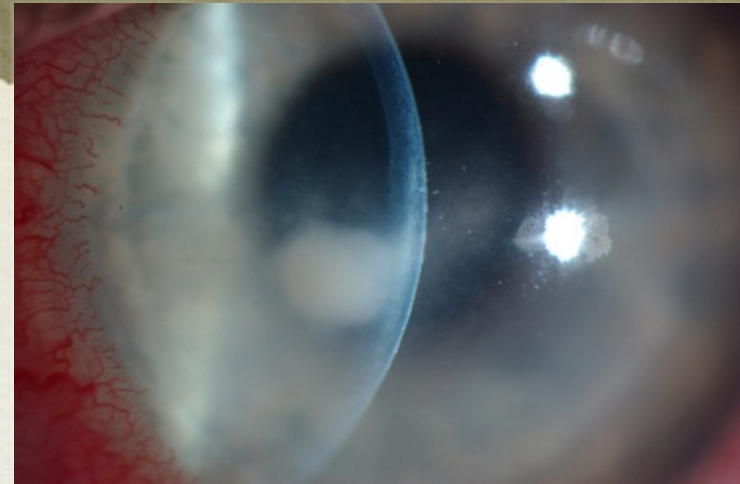


# Ulcers in Contact Lens Wearers

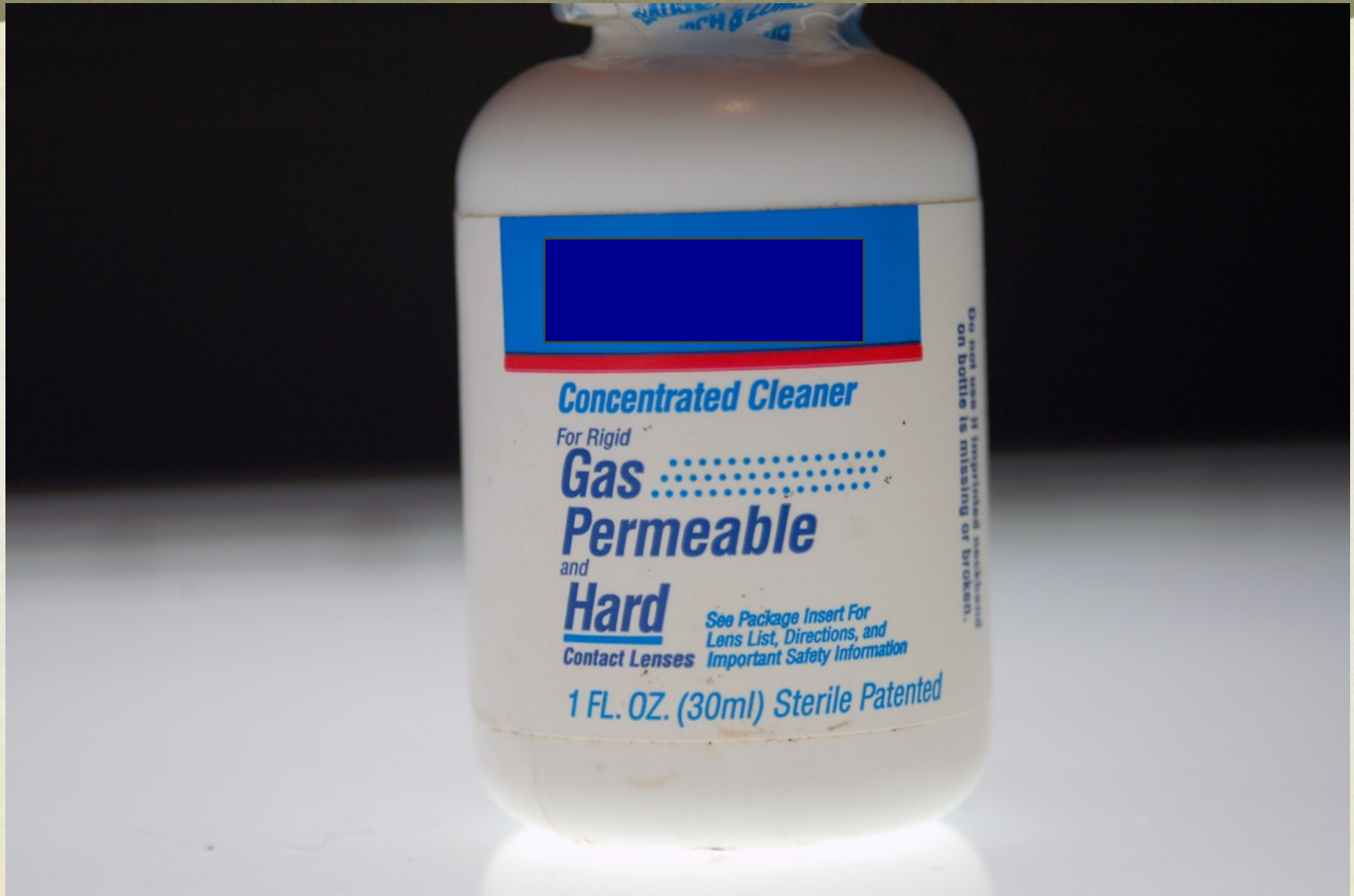- Often pseudomonas
- Don't forget acanthamoeba!
- Suspect if **dendritiform** lesion in CL wearer (think ACA, not HSV)
- Ask about overnight wear and tap water use. EDUCATE.

How to treat this? →

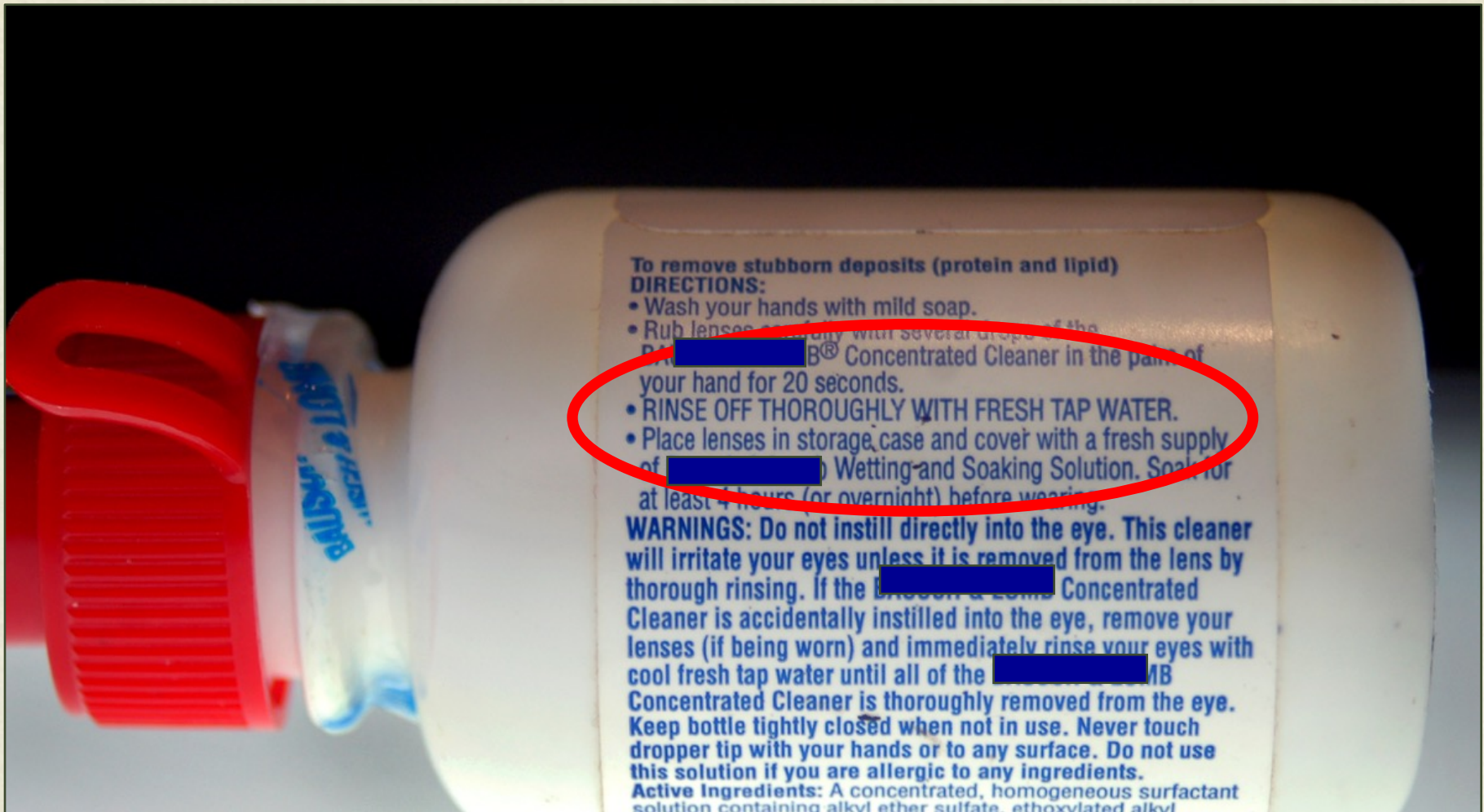
REMOVE EPITHELIUM, SEND TO LAB



# My patient's CL solution:



“Rinse off thoroughly with fresh tap water”



Very important....

**We need to report CL-related  
ulcers to FDA!**



Home Food



## MedWatch

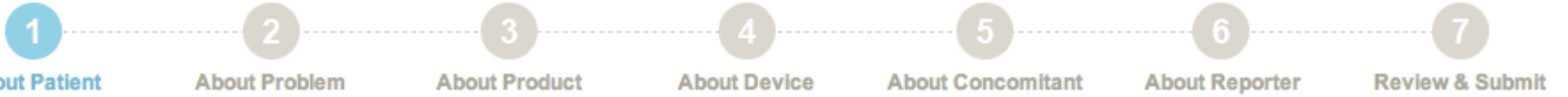### Welcome

#### What to Report to

Use the MedWatch for errors, product quality

- Prescription or over
- Biologics (including
- Medical devices (in
- Combination produc
- Special nutritional p
- Cosmetics
- Foods/beverages (i

## MedWatch Voluntary Report



### About Patient

#### Patient Identifier:

Please do NOT enter the Patient's Name or Social Security Number

#### Age or Date of Birth:

Unit OR

#### Sex:

Female  Male

#### Weight:

Unit

#### Ethnicity:

(Check single best answer)

Hispanic/Latino  Not Hispanic/Latino

#### Race:

(Check all that apply)

Asian  
 American Indian or Alaskan Native

1

About Patient

2

About Problem

3

About Product

4

About Device

5

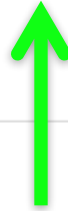About Concomitant

6

About Reporter

7

Review & Submit



## About Problem

\* Required Information

### Adverse Event, Product Problem:

(Check all that apply)

- Adverse Event ?
- Product Use Error ?
- Product Problem (e.g., de
- Problem with Different Ma

#### Adverse Event:

It is not necessary to be certain of a cause/effect relationship between the adverse event and the use of the medical product(s) in question. Suspicion of an association is sufficient reason to report. Submission of a report does not constitute an admission that medical personnel or the product caused or contributed to the event.

### Outcome Attributed to Ad

(Check all that apply)

- Death (include date)
- Life-threatening
- Hospitalization - initial or prolonged
- Disability or Permanent Damage ?
- Congenital Anomaly/Birth Defects
- Other Serious (Important Medical Events)
- Required Intervention to Prevent Permanent Impairment/Damage (Devices)

### Date of Event:

04/04/2016



### Describe Event, Problem, or Product Use Error: \*

infection from contact lens

Total of 4000 characters allowed. You have 3973 left.