

Visual fields Rules

Andrew G. Lee, MD

Houston, Texas

BCM

Baylor College of Medicine

THE UNIVERSITY OF TEXAS

MD Anderson
~~Cancer Center~~

Making Cancer History®

The logo for utmb Health, featuring the lowercase text "utmb" in white on a red square background, followed by the word "Health" in a grey serif font.

Working together to work wonders.™



Weill Cornell Medical College

HOUSTON
Methodist[™]
TEXAS MEDICAL CENTER



TEXAS A&M
**HEALTH
SCIENCE
CENTER**
COLLEGE OF
MEDICINE

The logo of the University of Iowa Health Care, featuring a stylized graphic of a building or a shield with a central emblem. The emblem consists of a central vertical element with two curved, leaf-like shapes on either side, all in shades of gold and grey.
**UNIVERSITY
of IOWA**
HEALTH CARE

1978: I wanted to be a doctor... 2nd NASA
& 3rd choice Jedi knight





THE FORCE AWAKENS PRESENTS A Lucasfilm Production A STAR WARS STORY

Starring **MAYN HAWKE HARRISON FORD CARRE FISHER**

PETER DINKLAGE

and **ADIC GUNNACIS**

Written and Directed by **GEORGE LUCAS**

Produced by **GARY RUTZ**

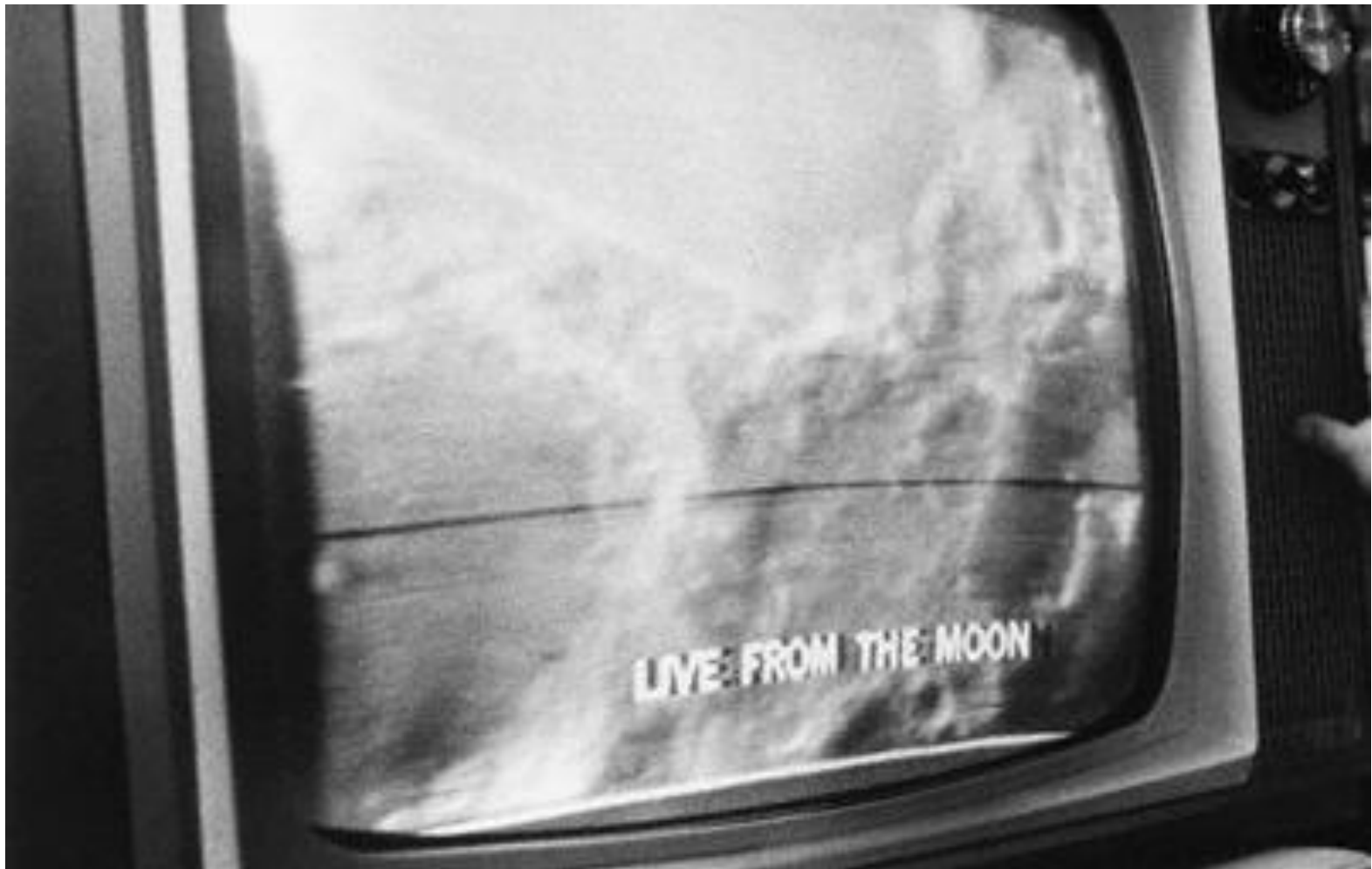Music by **JOHN WILLIAMS**

STAR WARS

REGULATED BY THE MPAA RATED PG-13 PARENTS STRONGLY CAUTIONED
[Some Material May Be Inappropriate for Children Under 13]



On July 20, 1969, I was 5 years old, the moon landing was on tv....



Don't forget to....

Fill out your evaluation forms
Vote for Speaker of the Day
Join me for the Banyan Tree
session



Meet your panel



Grant Liu MD

University of Pennsylvania

Andrew G. Lee MD

Houston Methodist

Randy Kardon MD PhD

University of Iowa

Meet your teachers for today



Andrew G. Lee, MD

Houston, Texas

Grant Liu, MD

Philadelphia, PA

Prem Subramanian, MD

Denver, CO

Randy Kardon MD, PhD

Iowa City, IA

Five questions for visual field interpretation

Is it a one eye (unilateral) or two eye defect (bilateral)

If bilateral, horizontal or vertical step (bitemporal or homonymous)

Is it denser superiorly or inferiorly? Up is up and down is down (except lateral geniculate body): Pie in the sky: Temporal and Pie on the floor: Parietal

If homonymous, RAPD + band atrophy = optic tract lesion

If homonymous, is there congruity, a temporal crescent or macular sparing? = more likely to be occipital

Visual Field Pathway

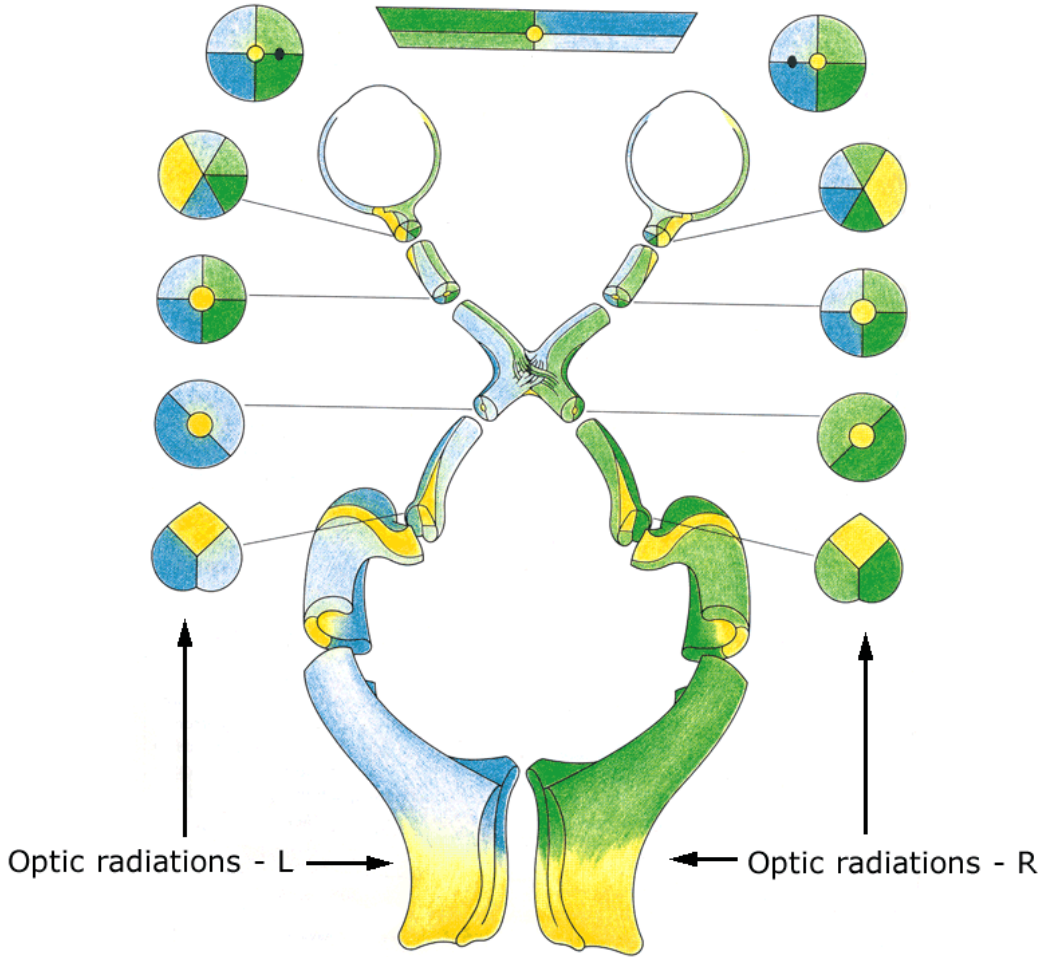
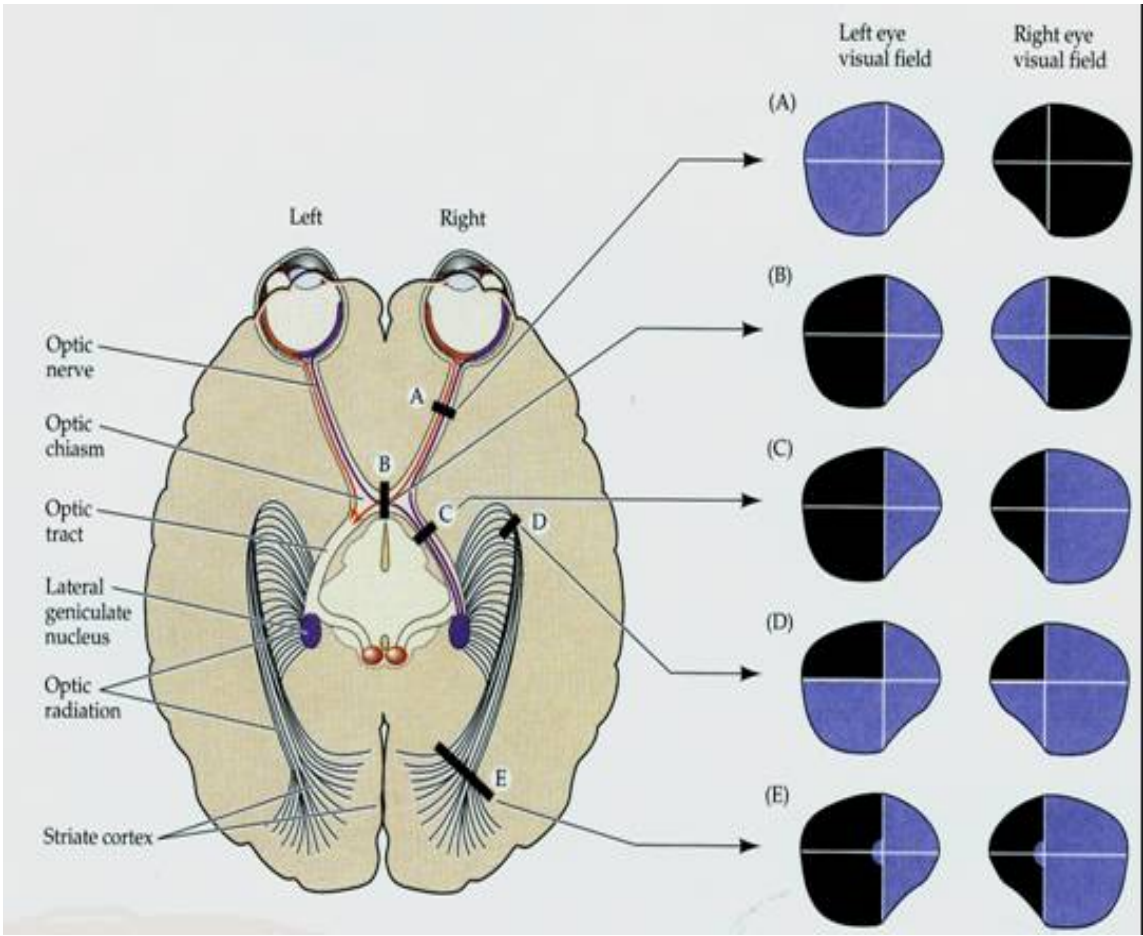
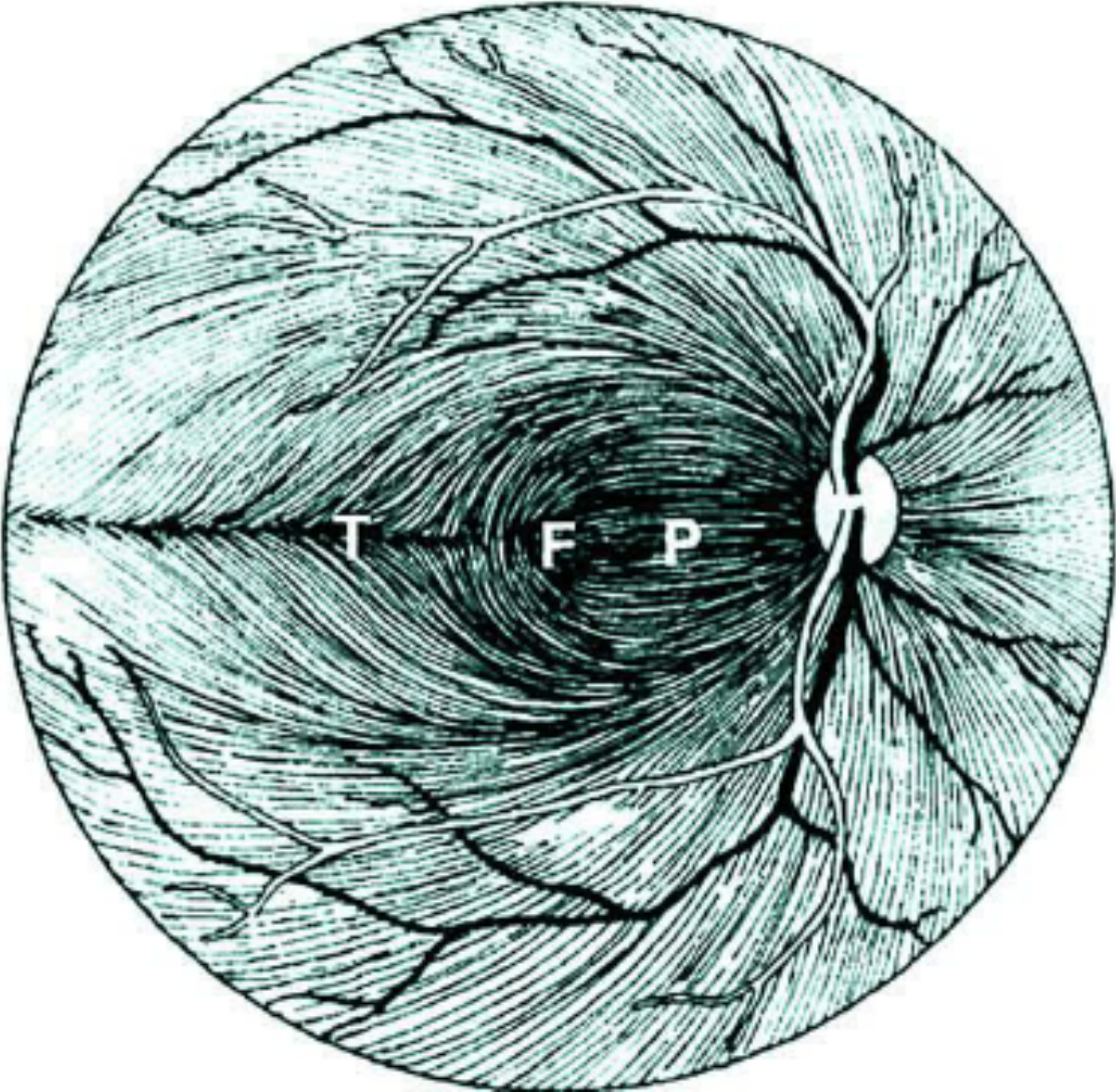


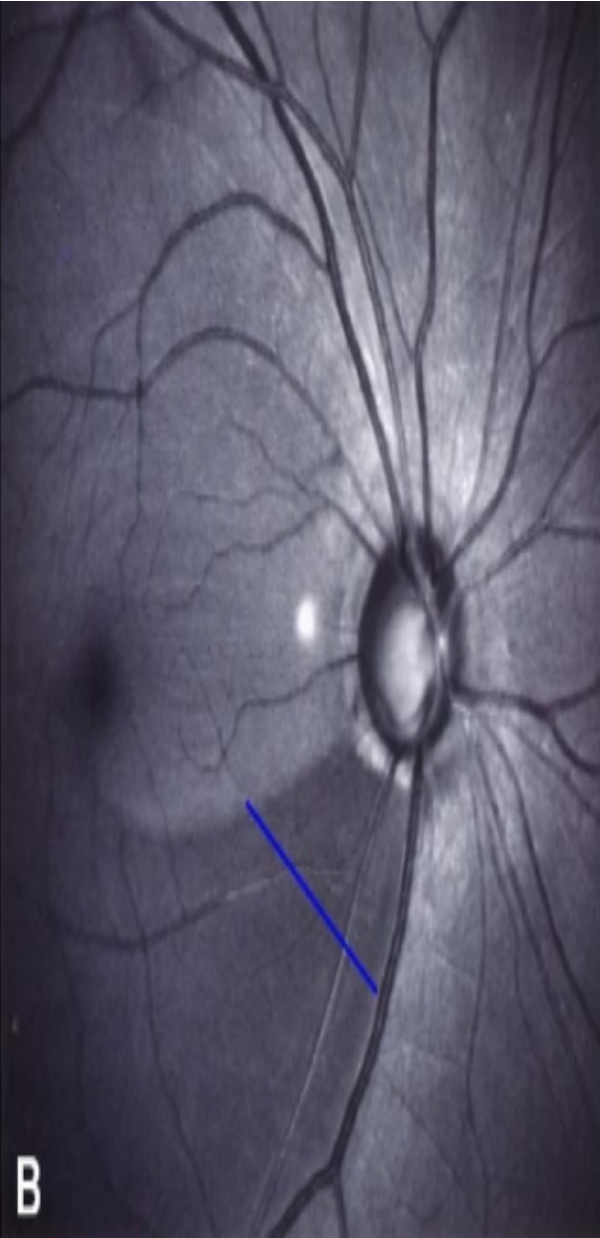
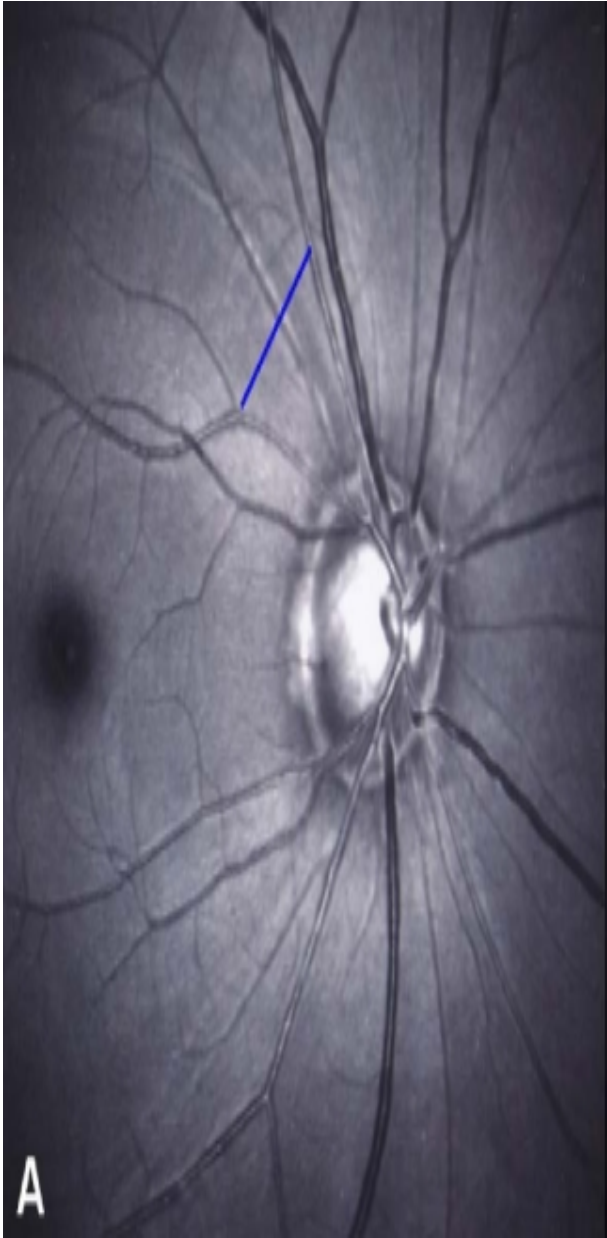
Fig. 1-14, Walsh TJ, Visual Fields, Am Acad Ophthal, 1996, VFs-12

The topography



Nerve fiber layer defects



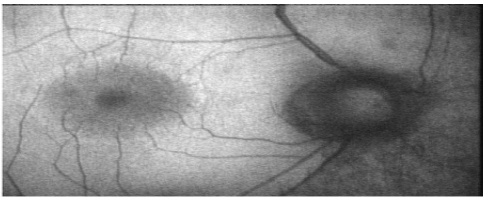


Ready...begin

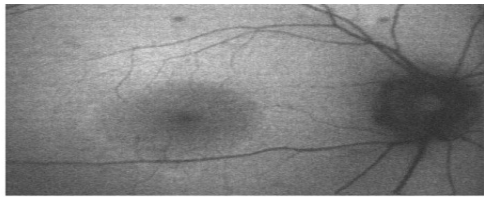
Who has a tumor and who has glaucoma?

Who has the retinal disease?

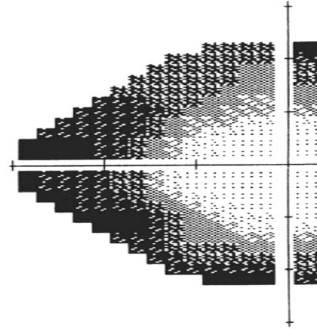
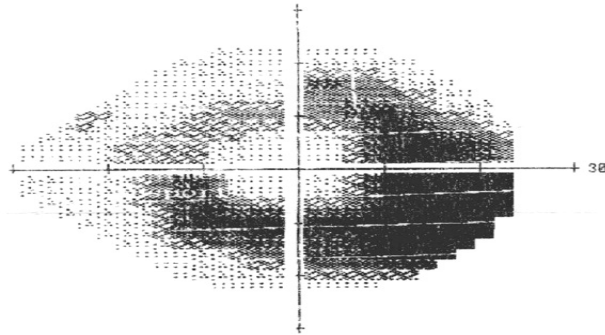
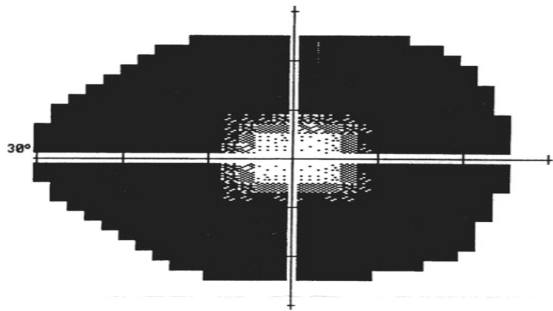
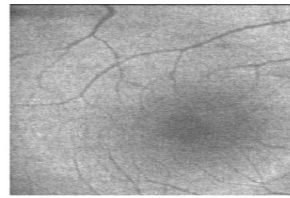
L



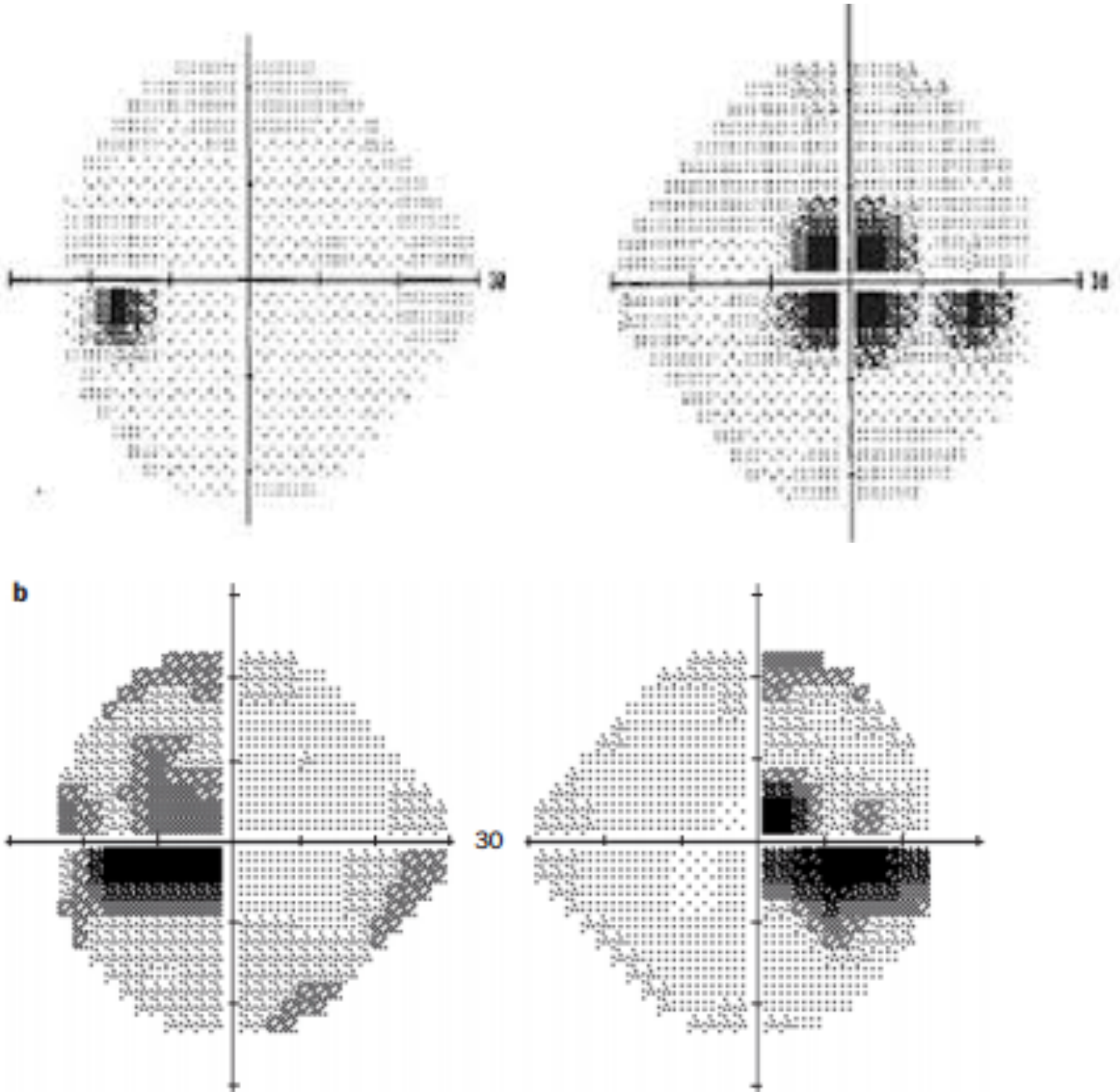
M

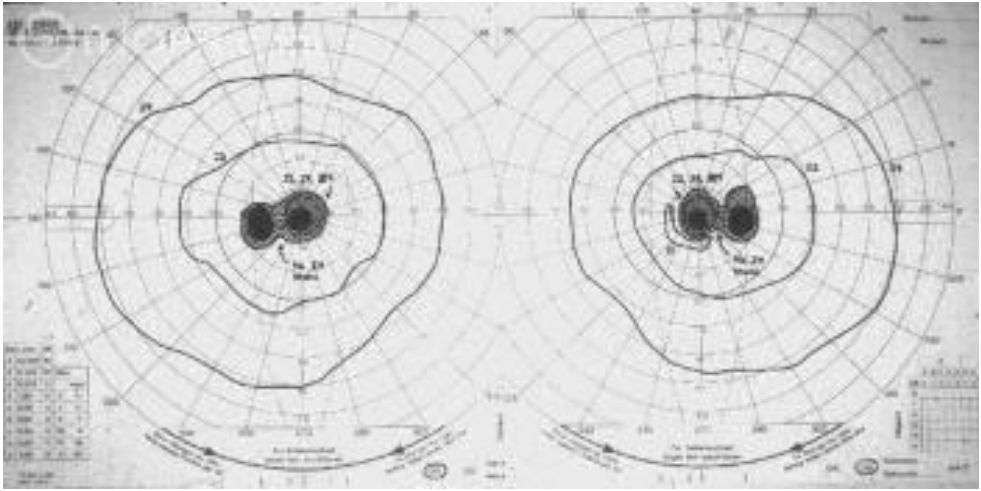


N

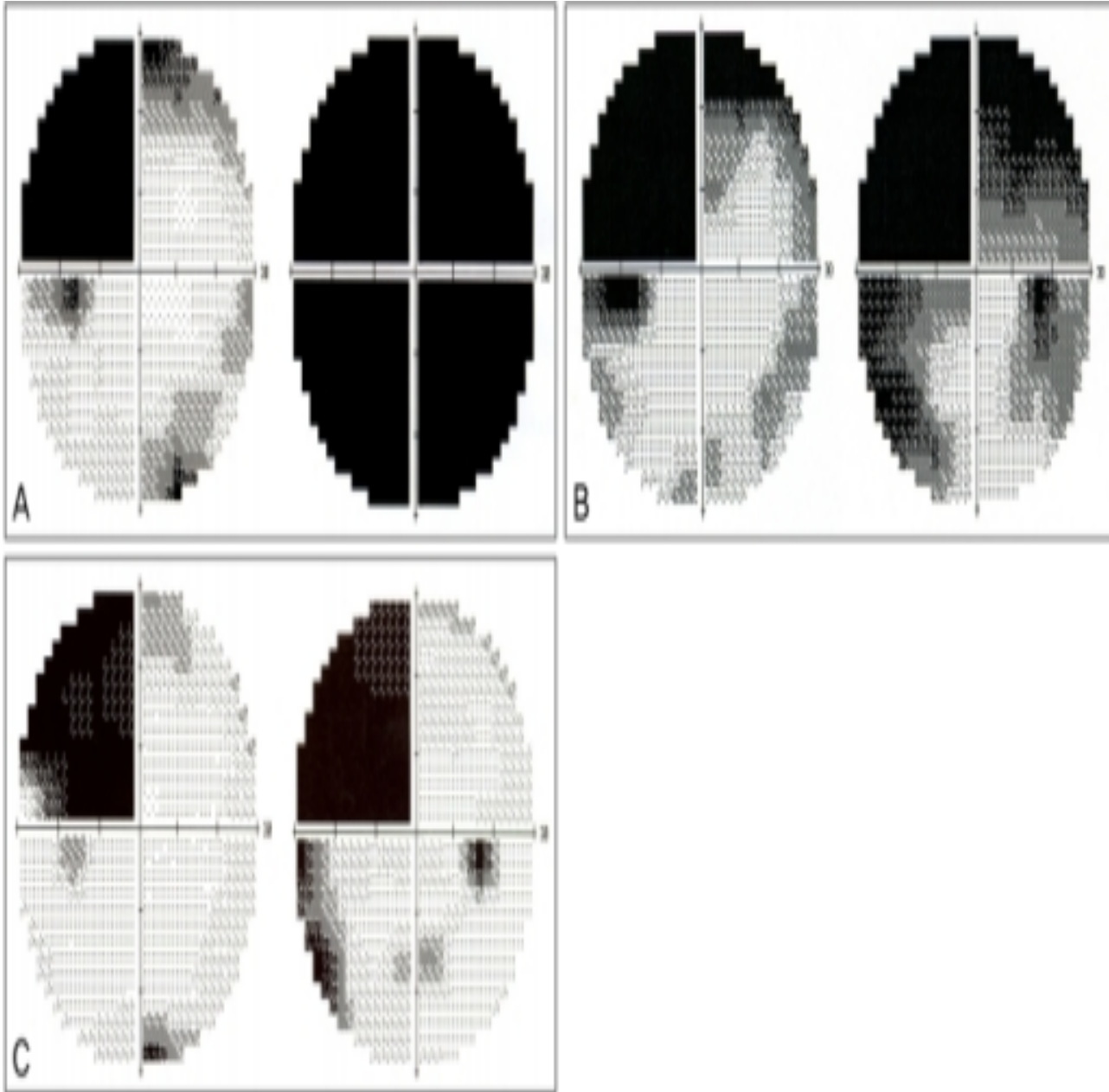


Who has toxic-nutritional optic neuropathy?

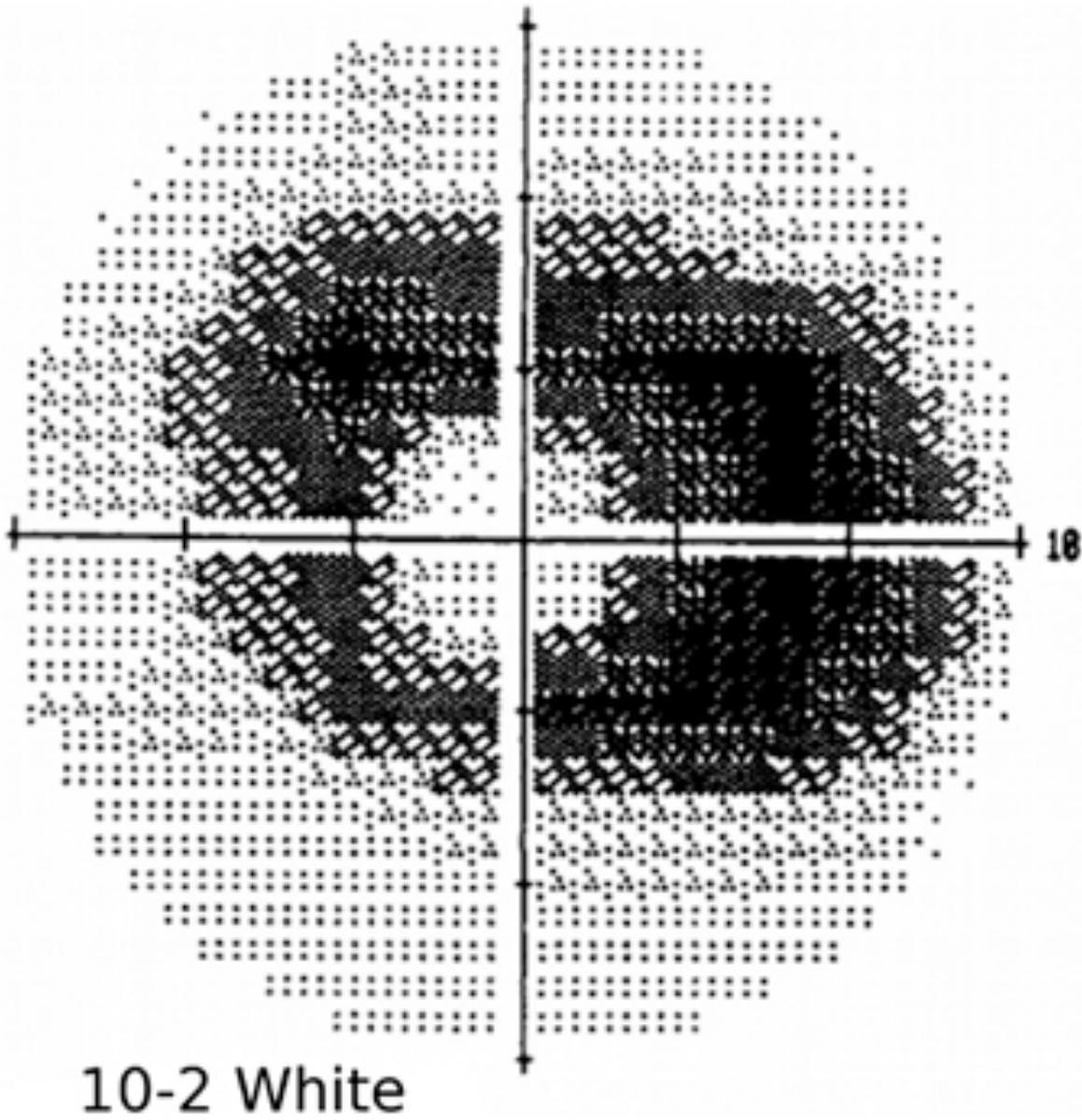


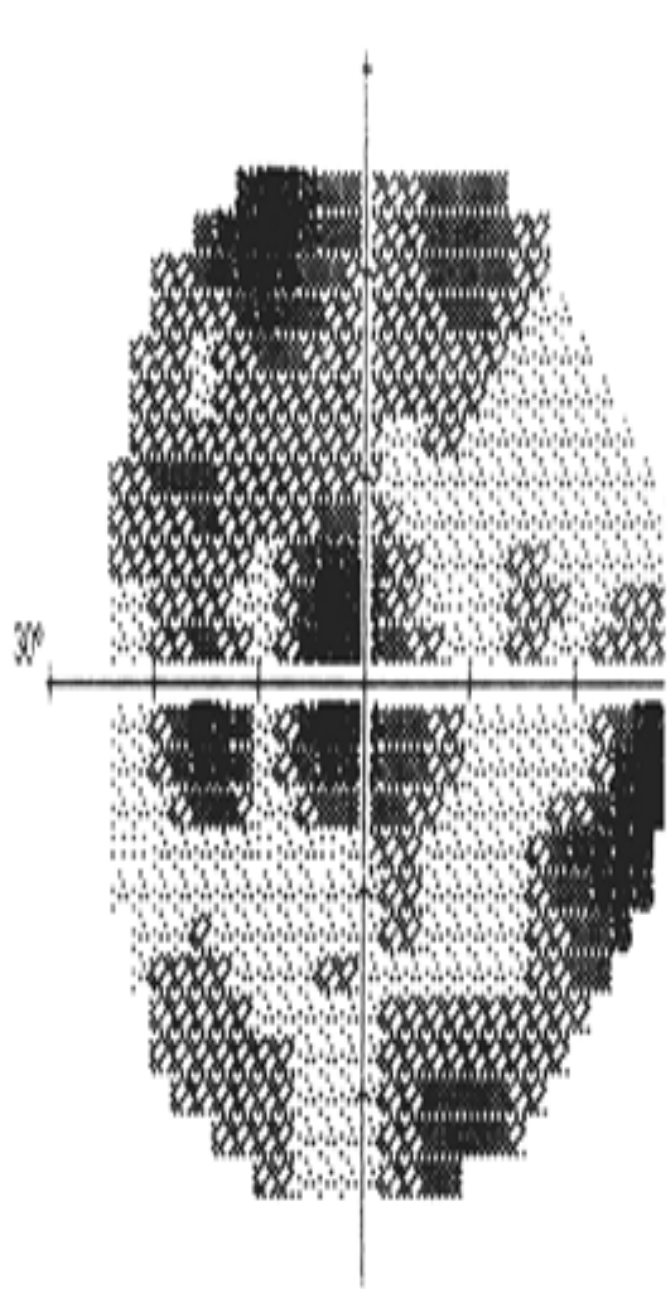


Who has the stroke and who has the tumor?

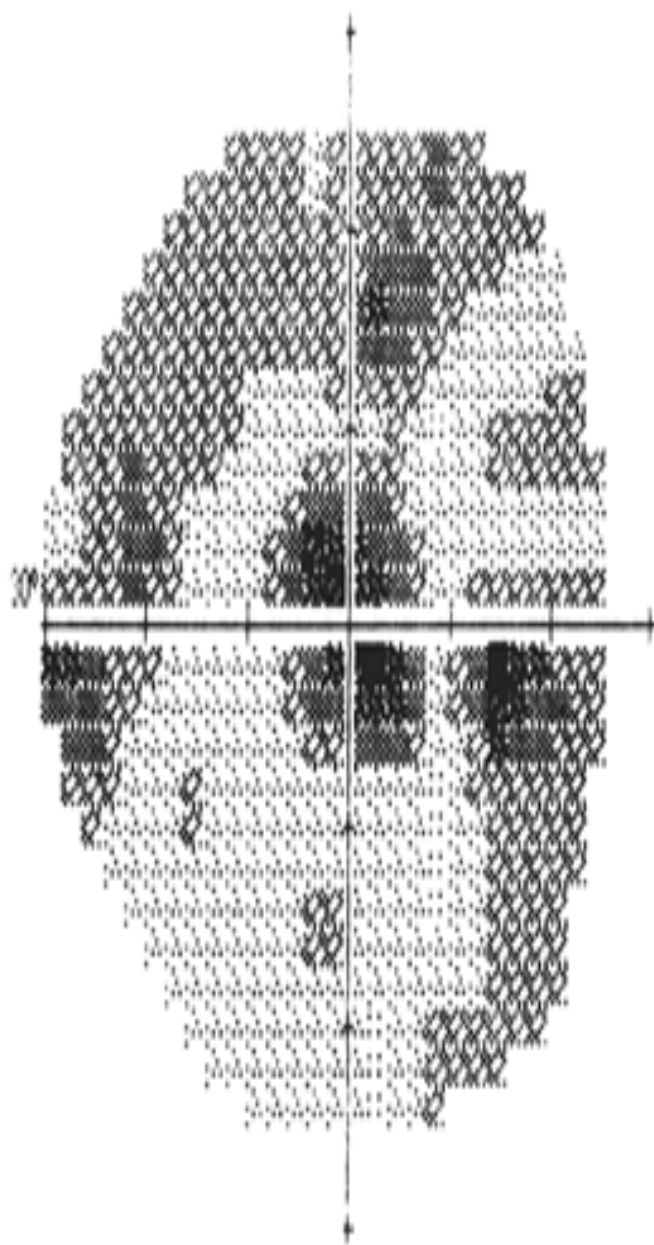


Who has hydroxychloroquine and who has ethambutol toxicity (10-2 HVF)?



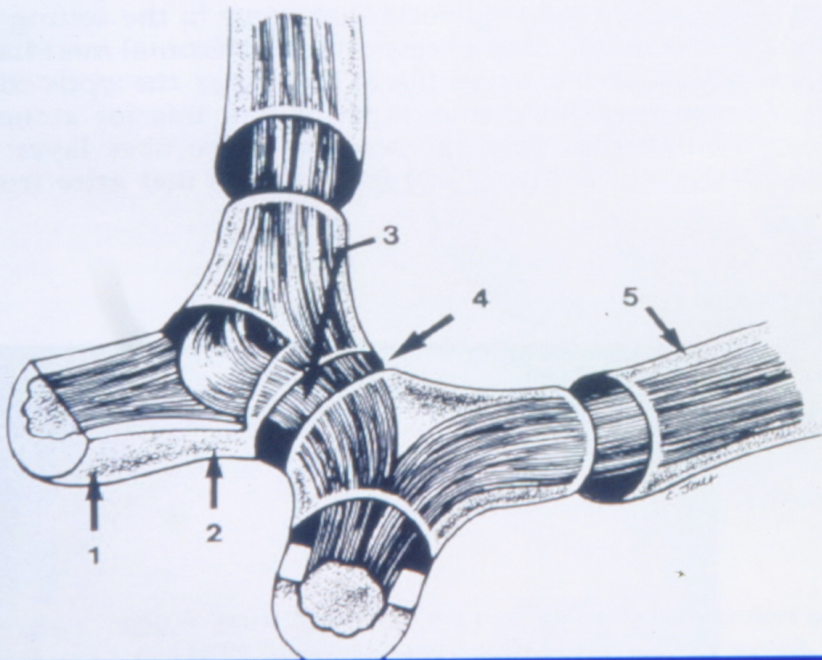


A



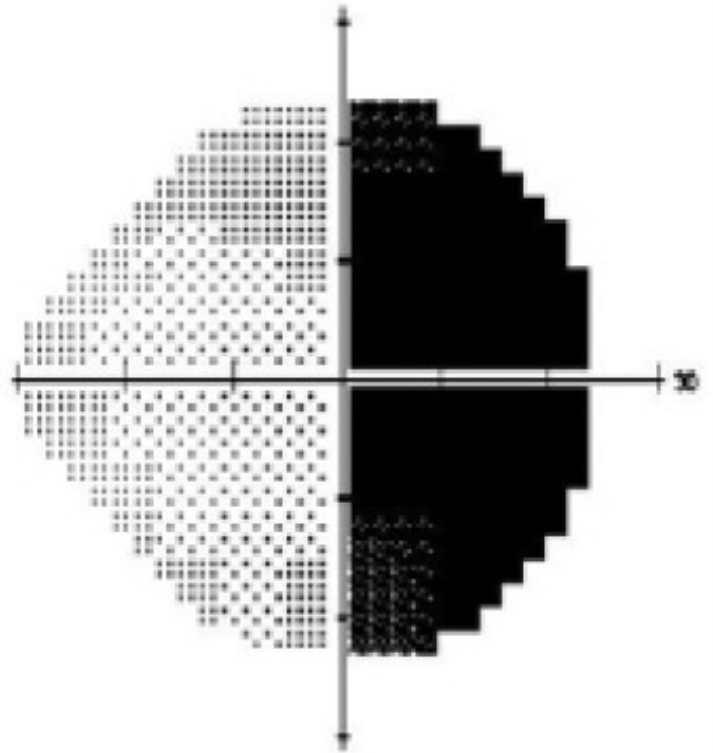
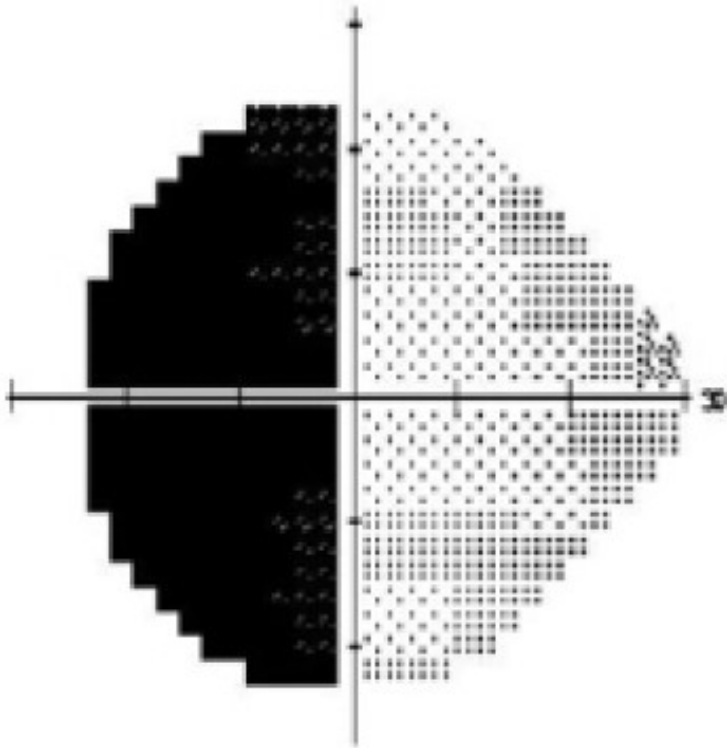
B

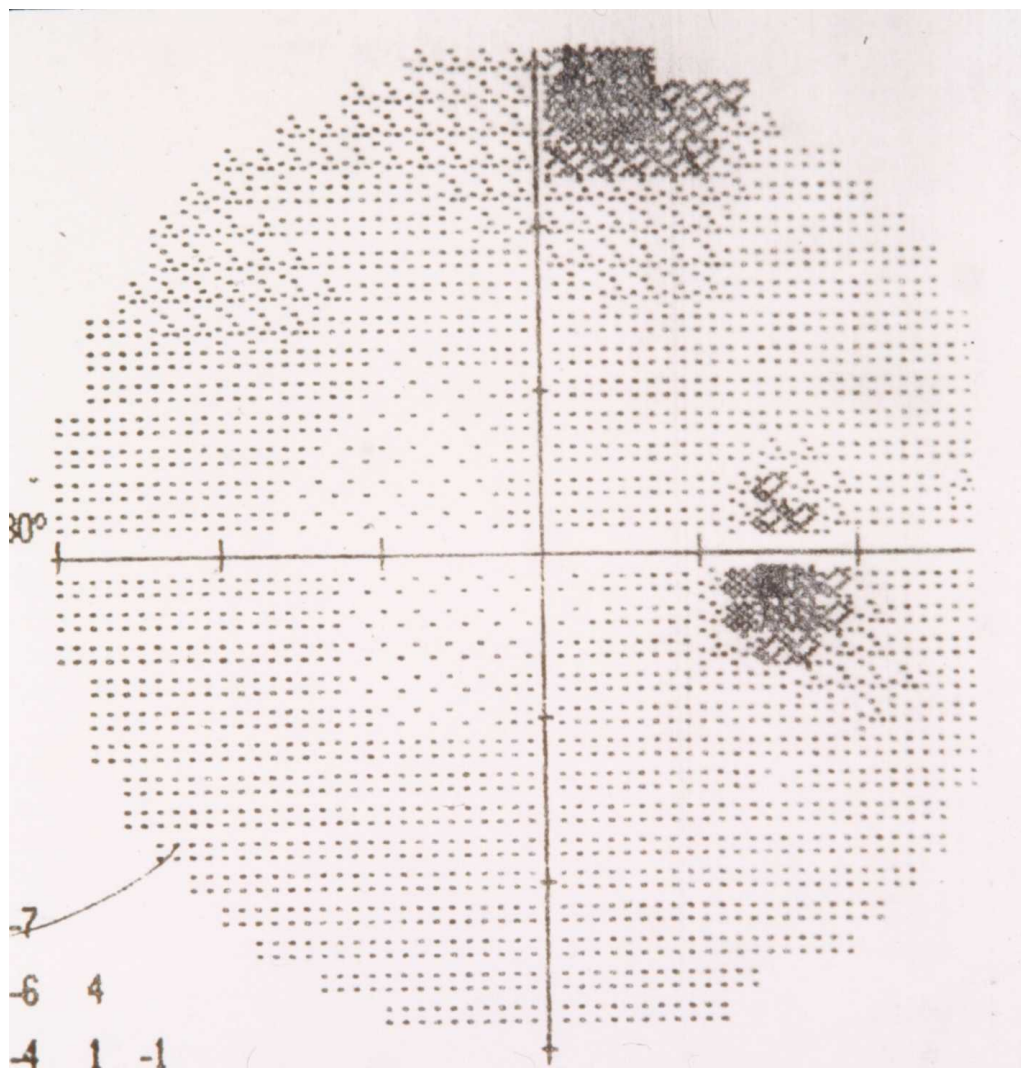
CHIASMAL SYNDROMES


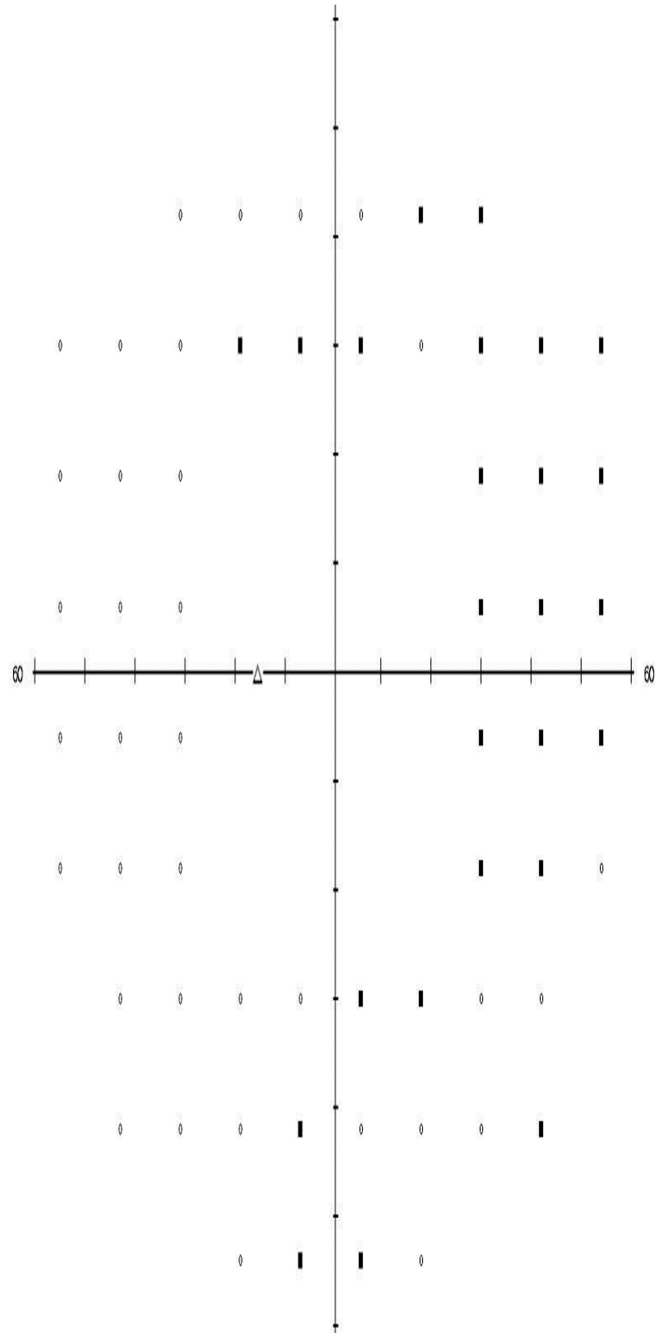
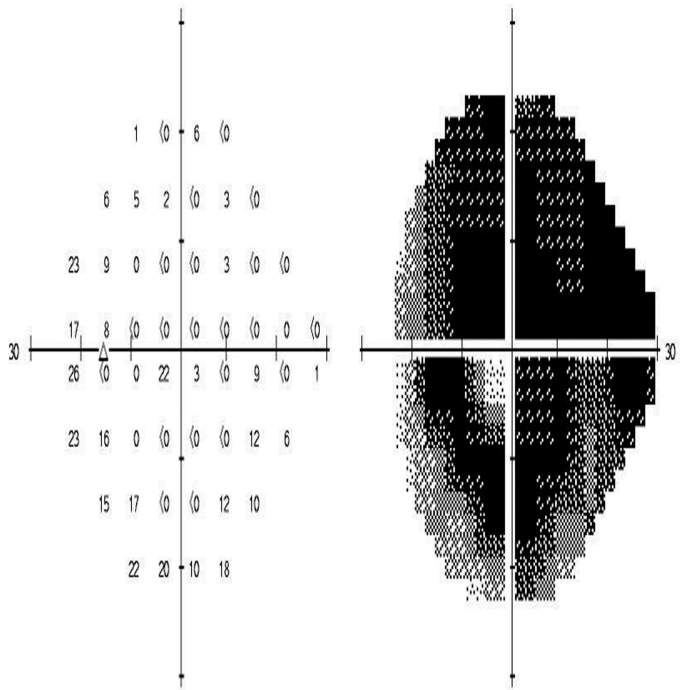


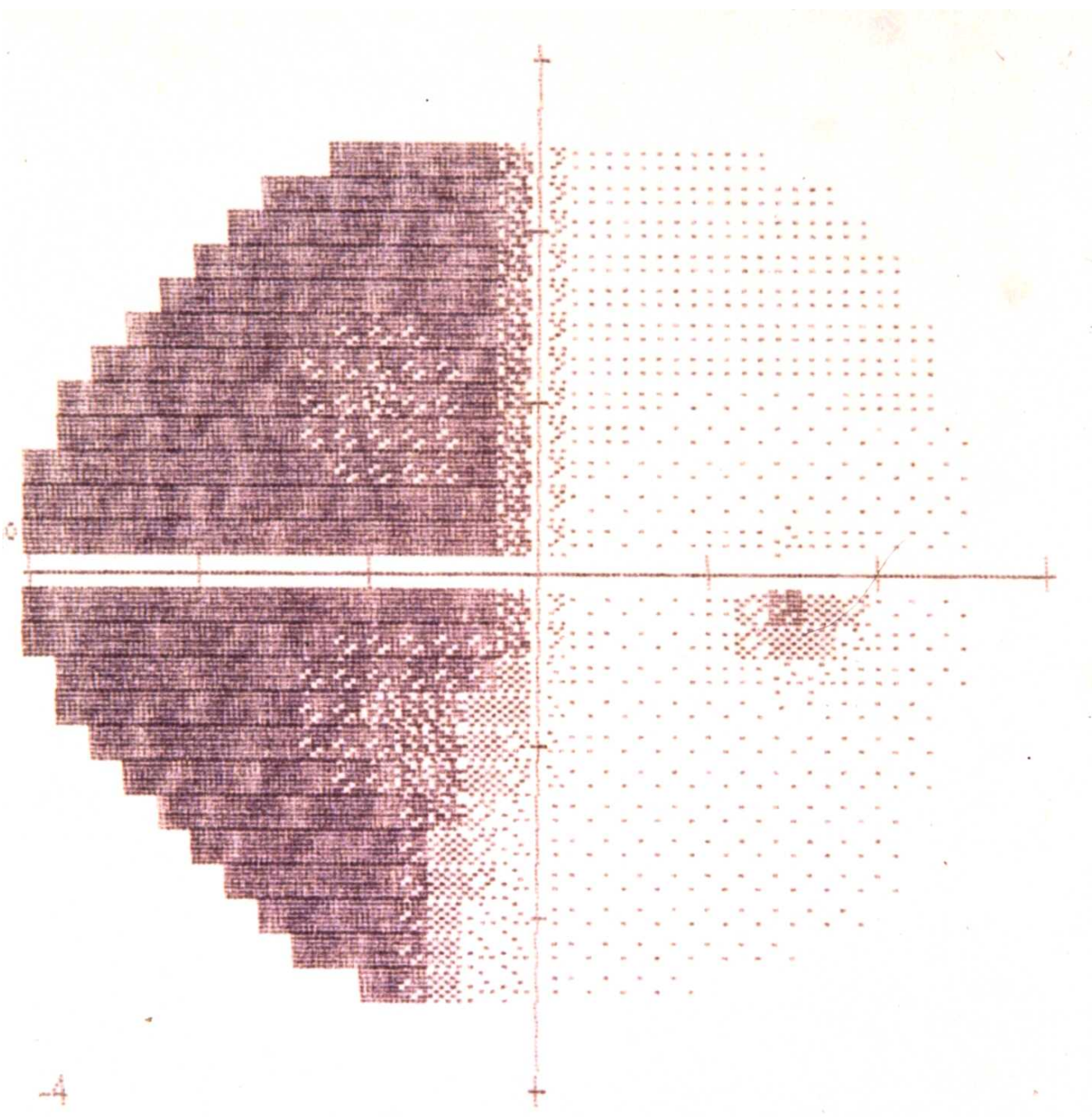
Location	Field Defect		Comment
	Left Eye	Right Eye	
1 Right Optic Nerve			No light perception right eye
2 Junction of Right Optic Nerve and Chiasm			Junctional syndrome
3 Chiasm			Bitemporal hemianopsia (classic)
4 Posterior Chiasm			Central bitemporal hemianopic scotomas
5 Left Optic Tract			Incongruous right homonymous hemianopia

Hoyt & Luis. Arch Ophthalmol 70:69, 1963.







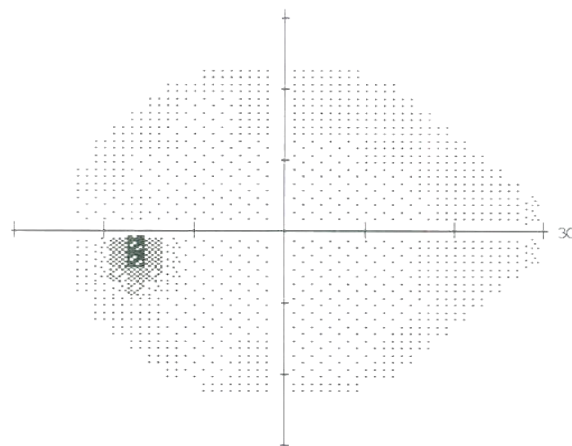



Fixation Monitor: Gaze/Blindspot
 Fixation Target: Central
 Fixation Losses: 1/10
 False POS Errors: 3 %
 False NEG Errors: 0 %
 Test Duration: 02:51

Stimulus: III, White
 Background: 31.5 ASB
 Strategy: SITA-Fast

Pupil Diameter:
 Visual Acuity:
 RX: DS DC X

Fovea: OFF



		2	2	1	0				
		0	2	0	0	-1	0		
		-2	0	2	0	0	-2	-1	-3
		0	2	0	1	0	-1	-4	-3
		-1	1	1	0	0	-2	-2	-4
		-1	-2	0	0	-2	0	-1	-2
		-3	0	-2	-1	0	-3		
		0	-2	0	-1				

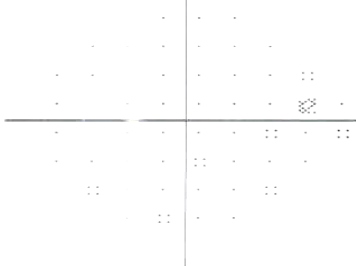
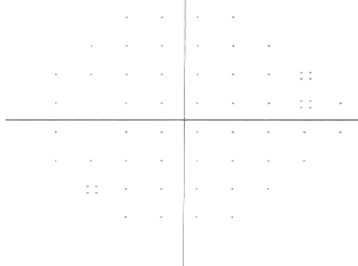
						1	0	-1					
						-2	-1	-1	-2	-2			
						-3	-1	-1	-1	-3	-2	-4	
						-1		-1	-1	-1	-2	-5	-4
						-2		0	-1	-2	-4	-3	-5
						-3	-3	-1	-1	-3	-2	-2	-3
						-4	-1	-3	-2	-2	-4		
							-3	-1	-2				

GHT
 Within normal limits

MD -0.56 dB
 PSD 1.43 dB

Total
 Deviation

Pattern
 Deviation

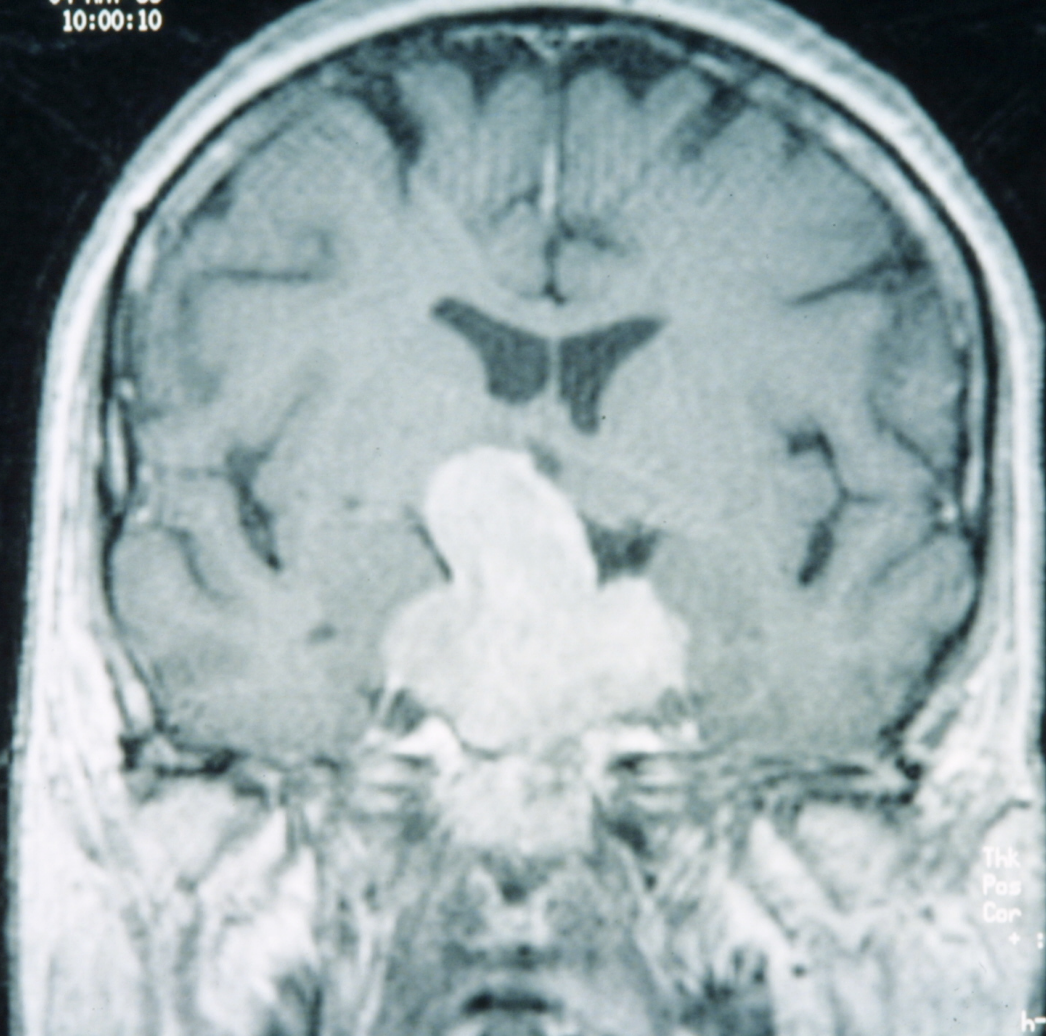


- :: < 5%
- ⊠ < 2%
- ⊞ < 1%
- < 0.5%

David L. Prudhomme OD
 3505 Pemberton Square Blvd
 Suite 45
 Vicksburg, MS 39180
 601-630-9199




167 lbs
POST GAD
10:00:10





SE1 90
TR 704
TE 14
TA 4:55
ACQ 2
FOV 180.0
M 192W256 o

Thk 3.0
Pos 5.6
Cor + : F A L
h-s A2

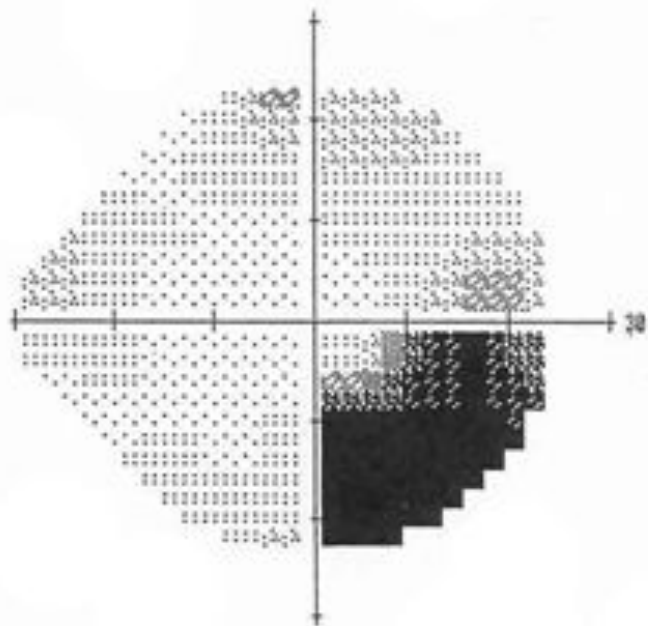

Left Eye




Right Eye




Hill: 0

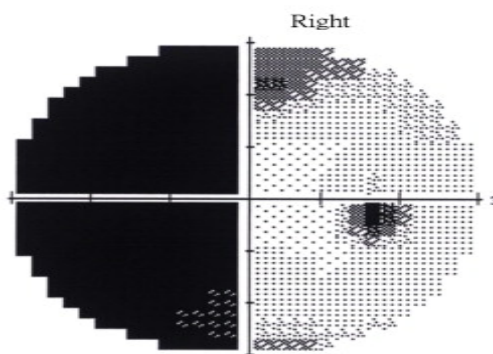
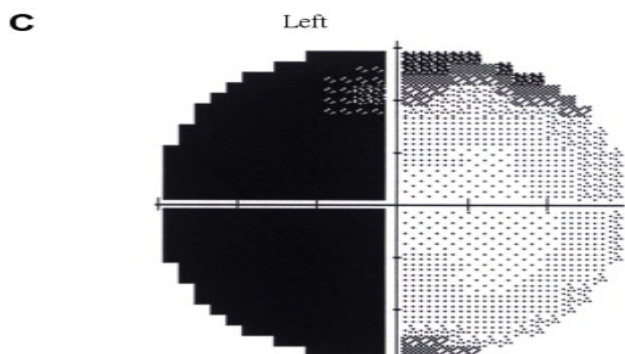
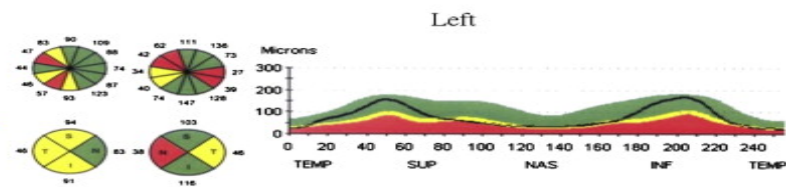
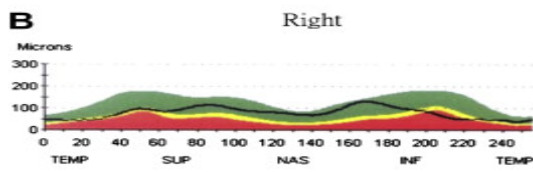
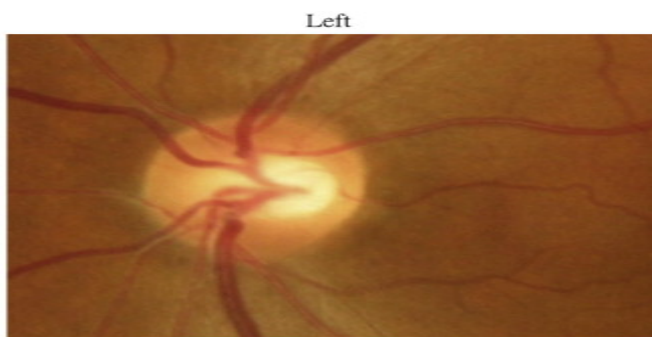
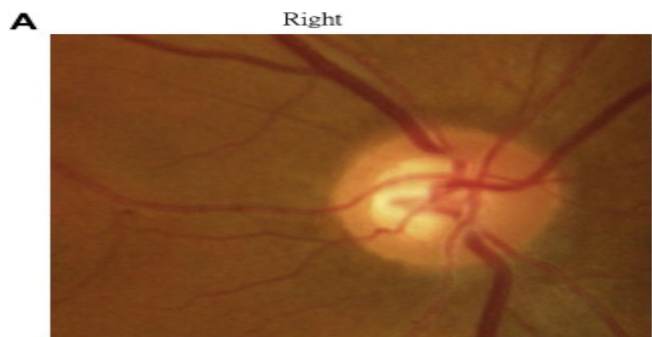


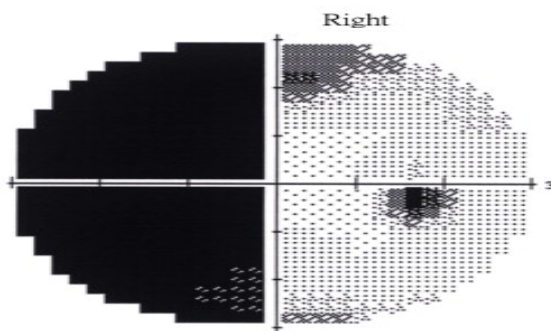
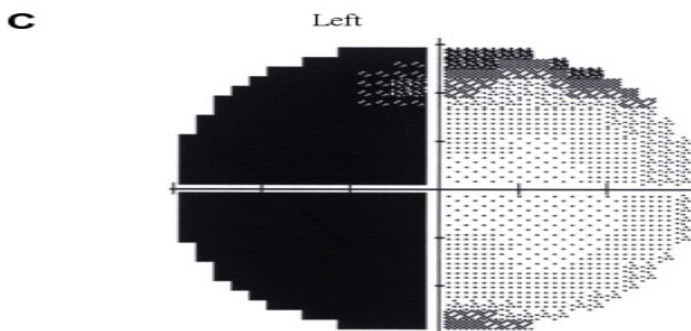
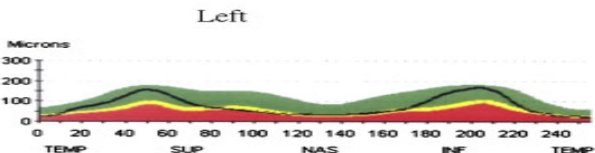
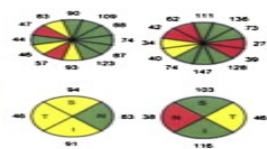
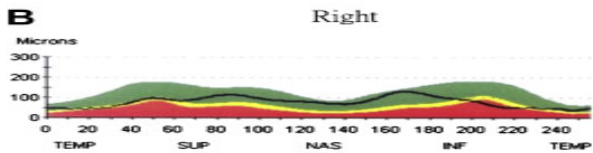
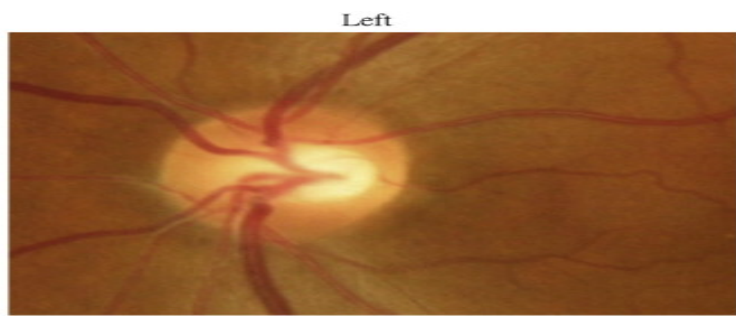
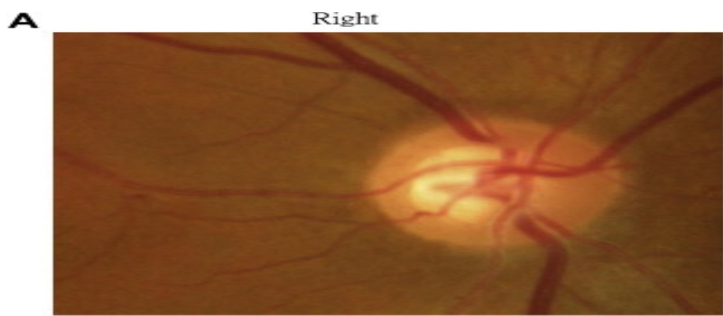
PATTERN
DEVIATION



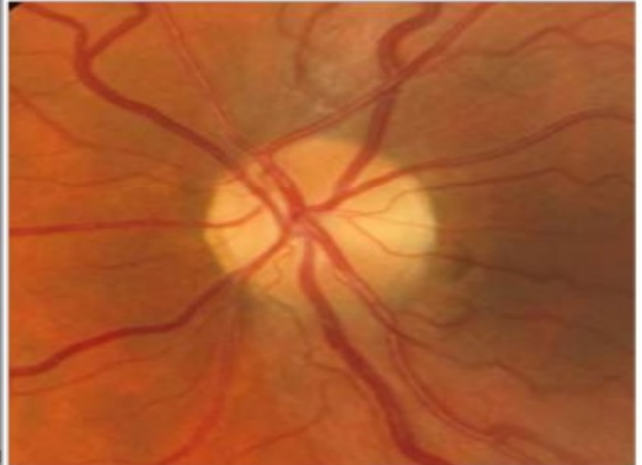
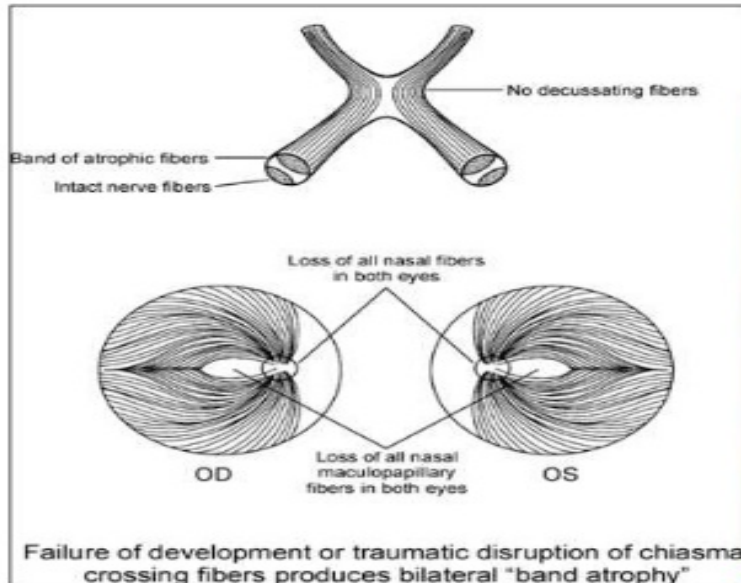
PATTERN
DEVIATION




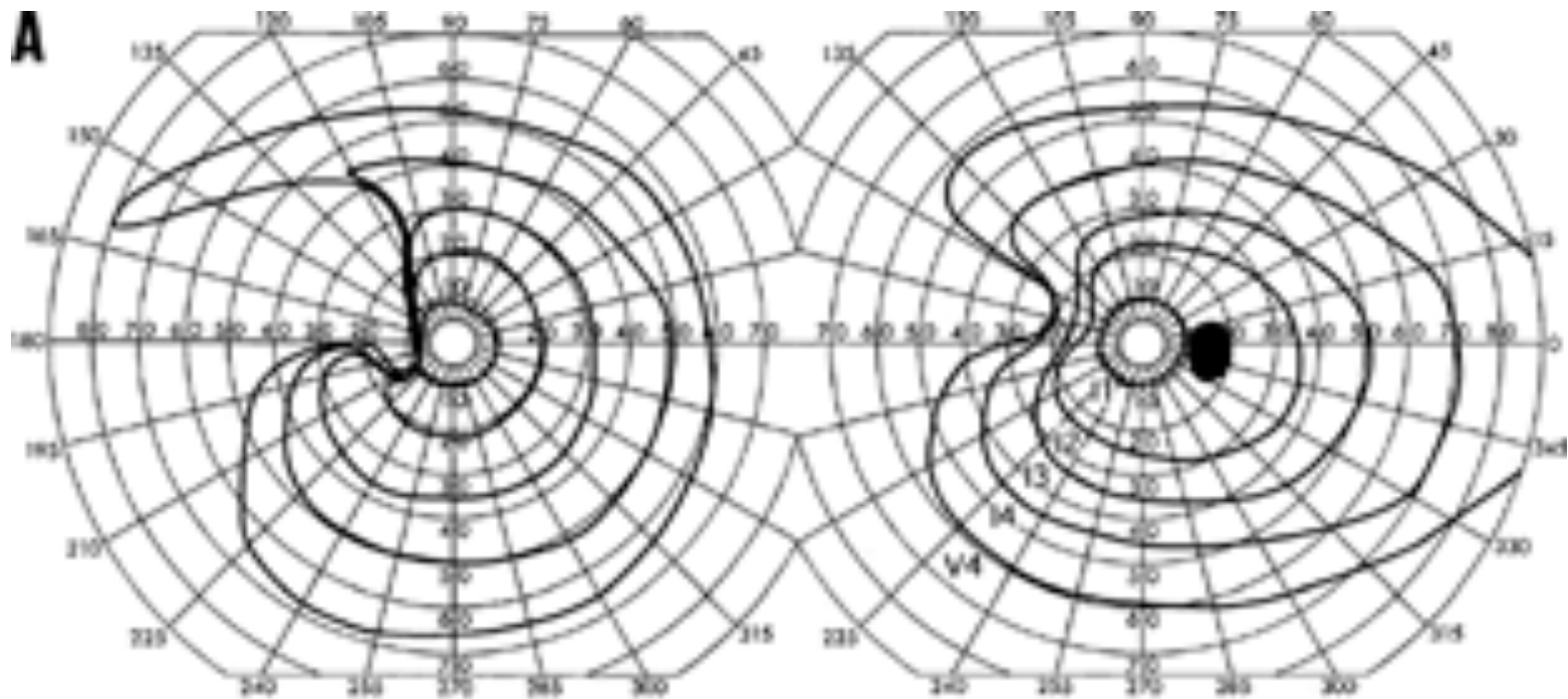


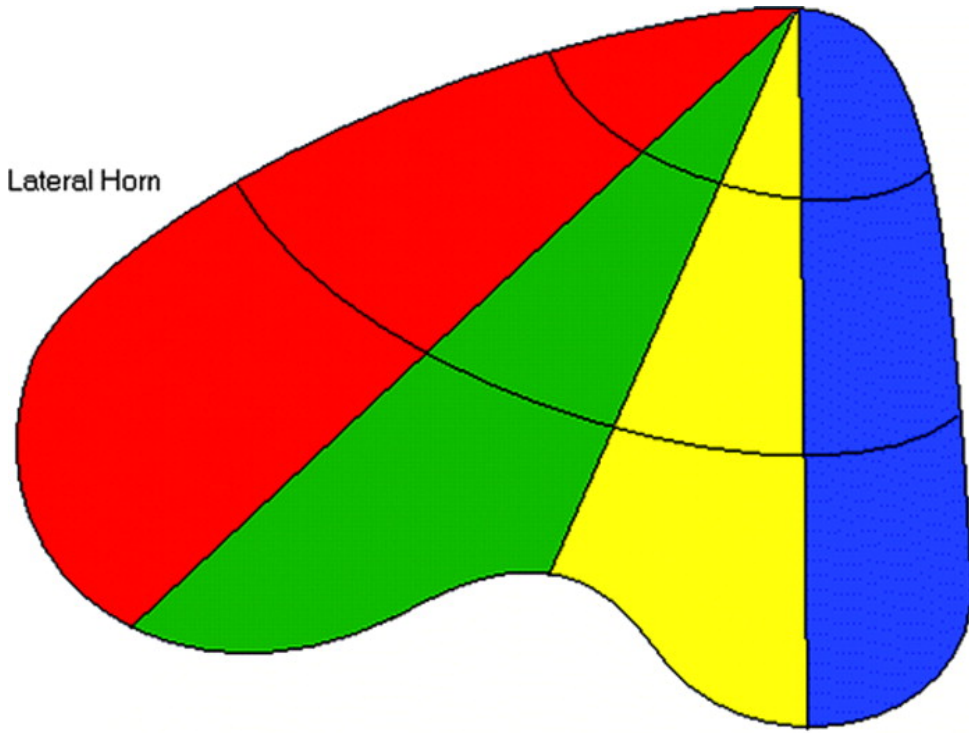


Band Atrophy

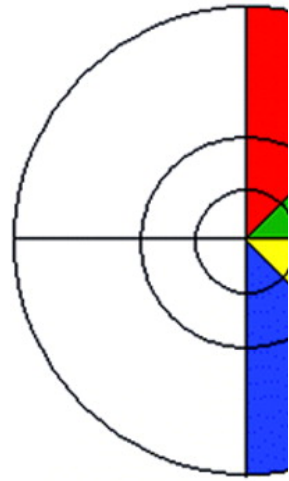


Band atrophy of optic nerve








Representation of right visual field in the left LGB, seen in coronal section from behind.



- Anterior
- Lateral (
- Lateral (
- Anterior











Hourglass-
shaped
visual fields
as a sign of
bilateral
lateral
geniculate
myelinolysis.

Am J Ophthalmol. 1995 Mar;119(3):378-80.












Hourglass-
shaped
visual fields
as a sign of
bilateral
lateral
geniculate
myelinolysis.

Am J Ophthalmol. 1995 Mar;119(3):378-80.

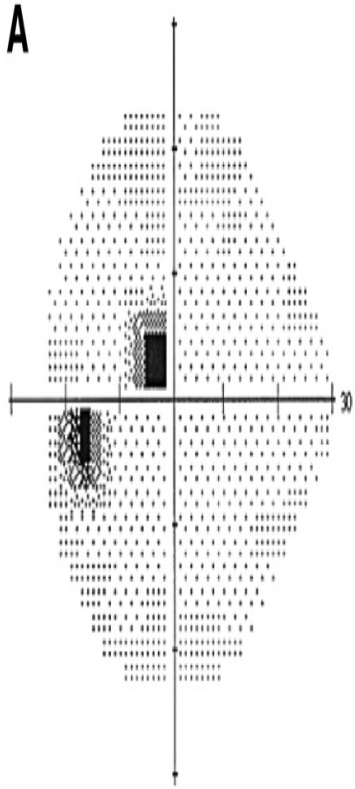
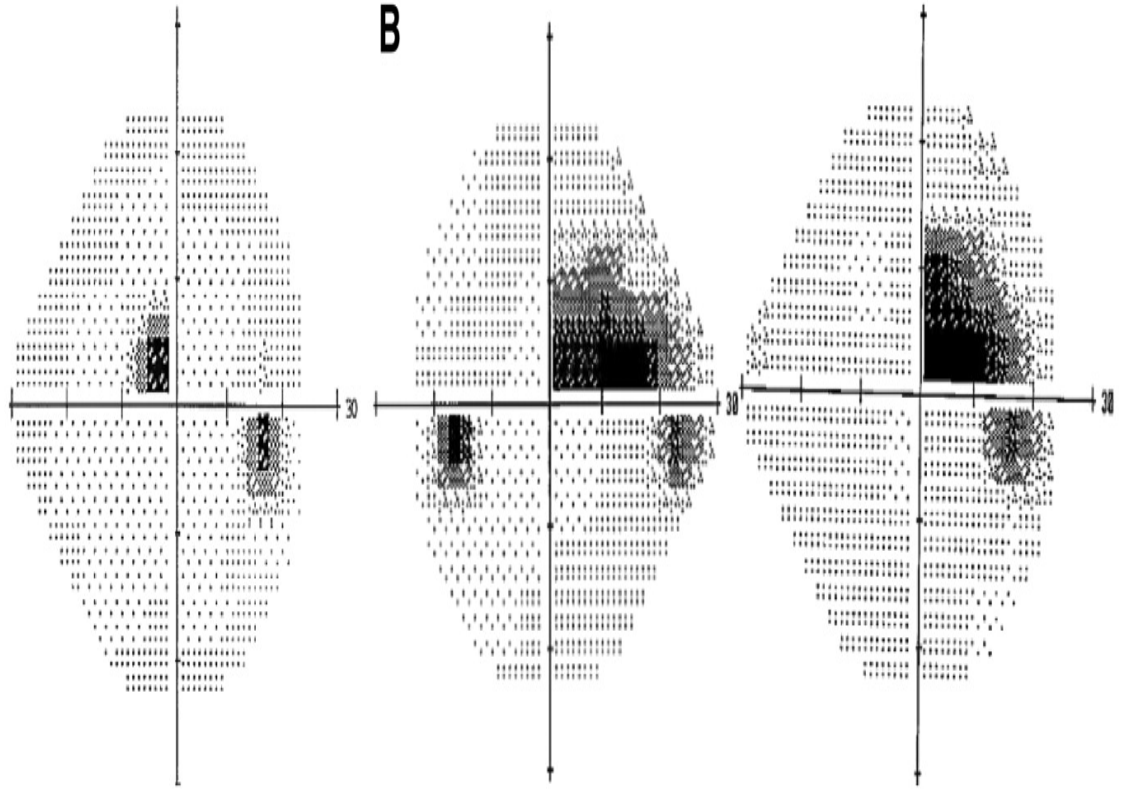
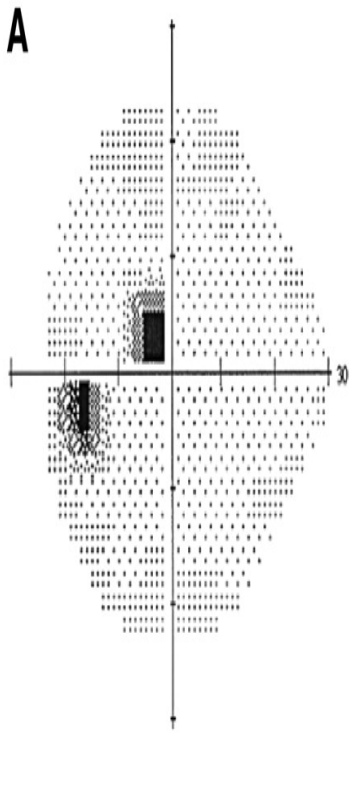
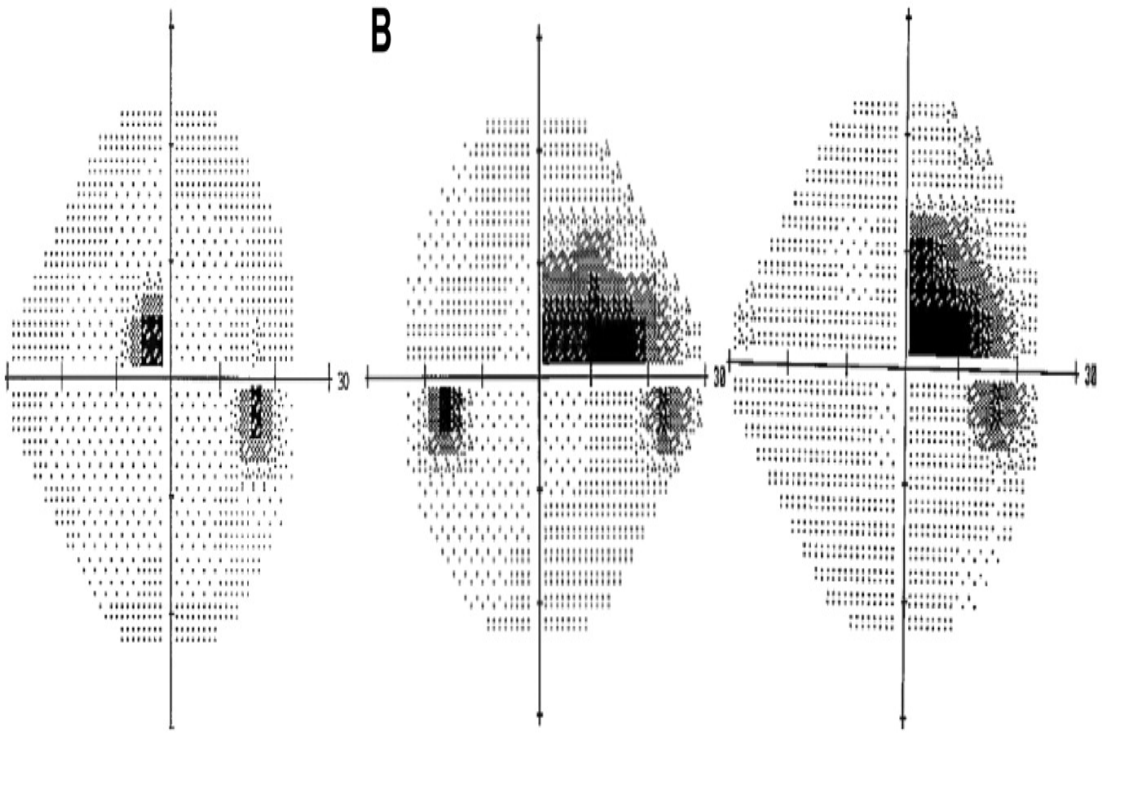


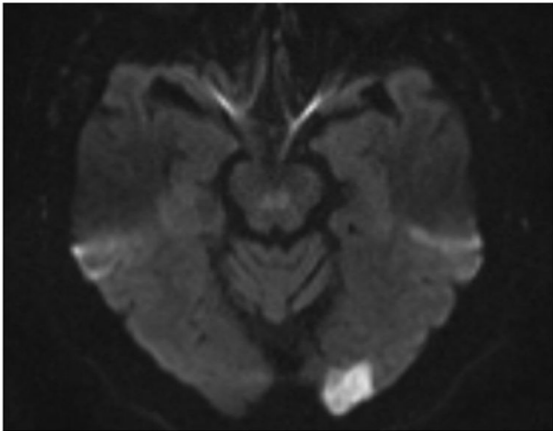


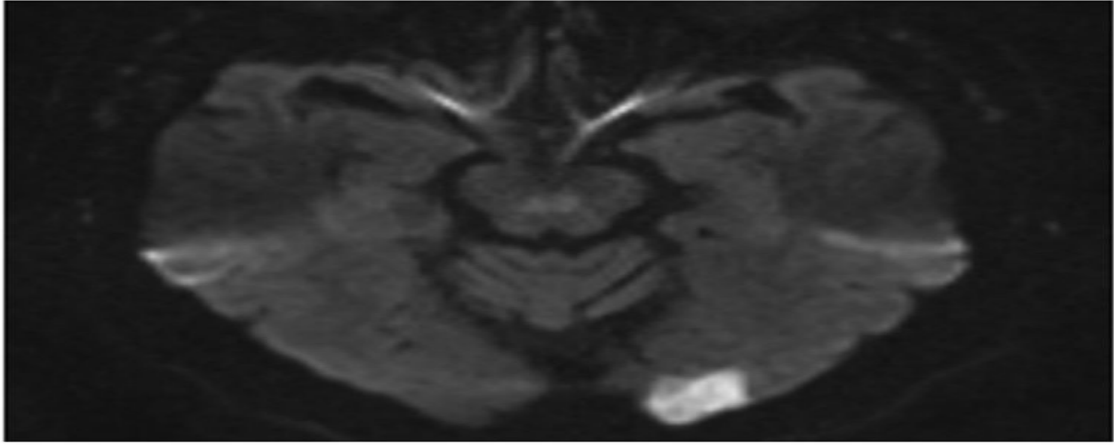






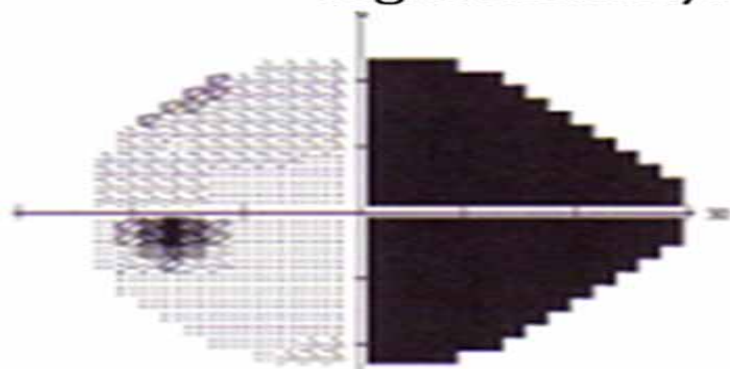
AJO 1995:119:378-90.

www.mrcophth.com

A**B****A****B**




Right Homonymous Hemianopia




MD : -8.98 dB ; P<0.5%

Left eye




MD : -13.42 dB ; P<0.5%

Right eye



MD : -16.57 dB ; P<0.5%

Left eye



MD : -12.12 dB ; P<0.5%

Right eye

Single Field Analysis

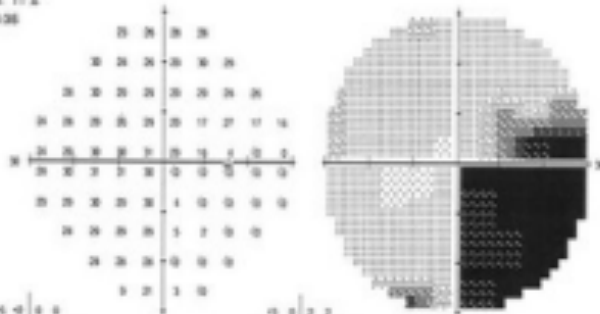
Eye: Right

Name: _____ DOB: 01-01-1994
 ID: _____

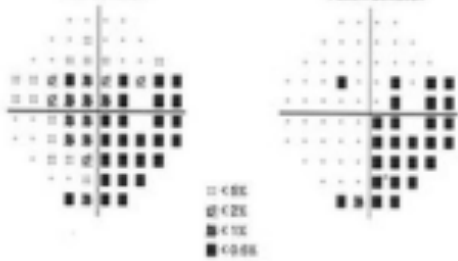
Central 30-2 Threshold Test

Fixation Monitor: Gaze/Blind Spot Stimulus: H, White Pupil Diameter: _____ Date: 10-12-2010
 Fixation Target: Central Background: 31.5 ASB Visual Acuity: _____ Time: 15:17
 Fixation Losses: 1/15 Strategy: STA-Fast Rx: OS OC X Age: 16
 False POS Errors: 0 %
 False NEG Errors: 11 %
 Test Duration: 04:35

Fovea: OFF



GHT
 Outside normal limits
 VFI: 72%
 MD: -12.00 dB P < 0.05
 PSD: 14.46 dB P < 0.05



© 2007 Carl Zeiss Meditec
 IFA 0 745-8508-4.2/4.2

Single Field Analysis

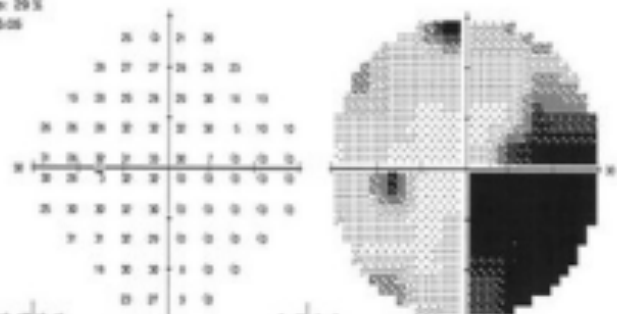
Eye: Left

Name: _____ DOB: 01-01-1994
 ID: _____


Central 30-2 Threshold Test

Fixation Monitor: Gaze/Blind Spot Stimulus: H, White Pupil Diameter: _____ Date: 10-12-2010
 Fixation Target: Central Background: 31.5 ASB Visual Acuity: _____ Time: 15:23
 Fixation Losses: 0/15 Strategy: STA-Fast Rx: OS OC X Age: 16
 False POS Errors: 4 %
 False NEG Errors: 29 %
 Test Duration: 05:05

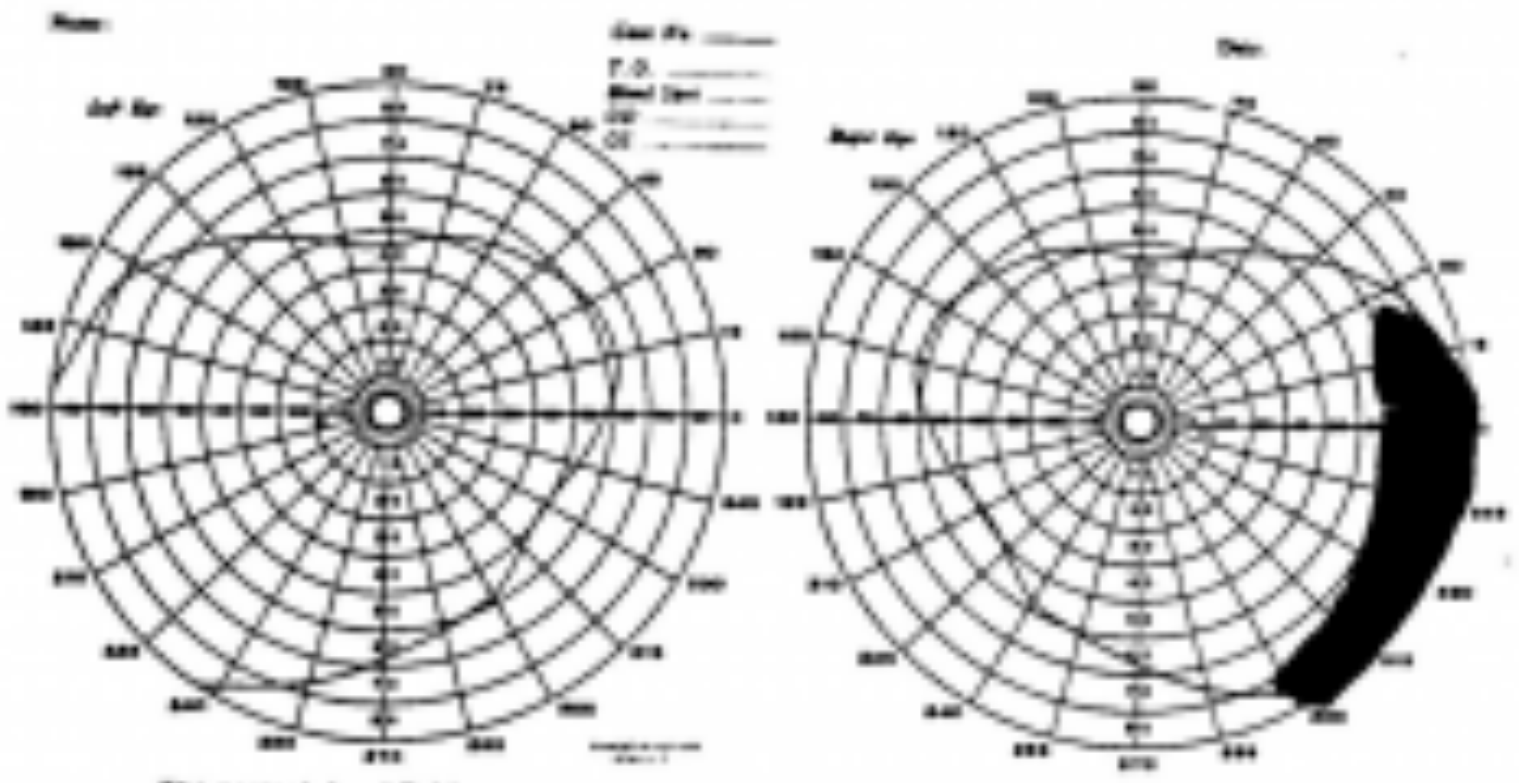
Fovea: OFF




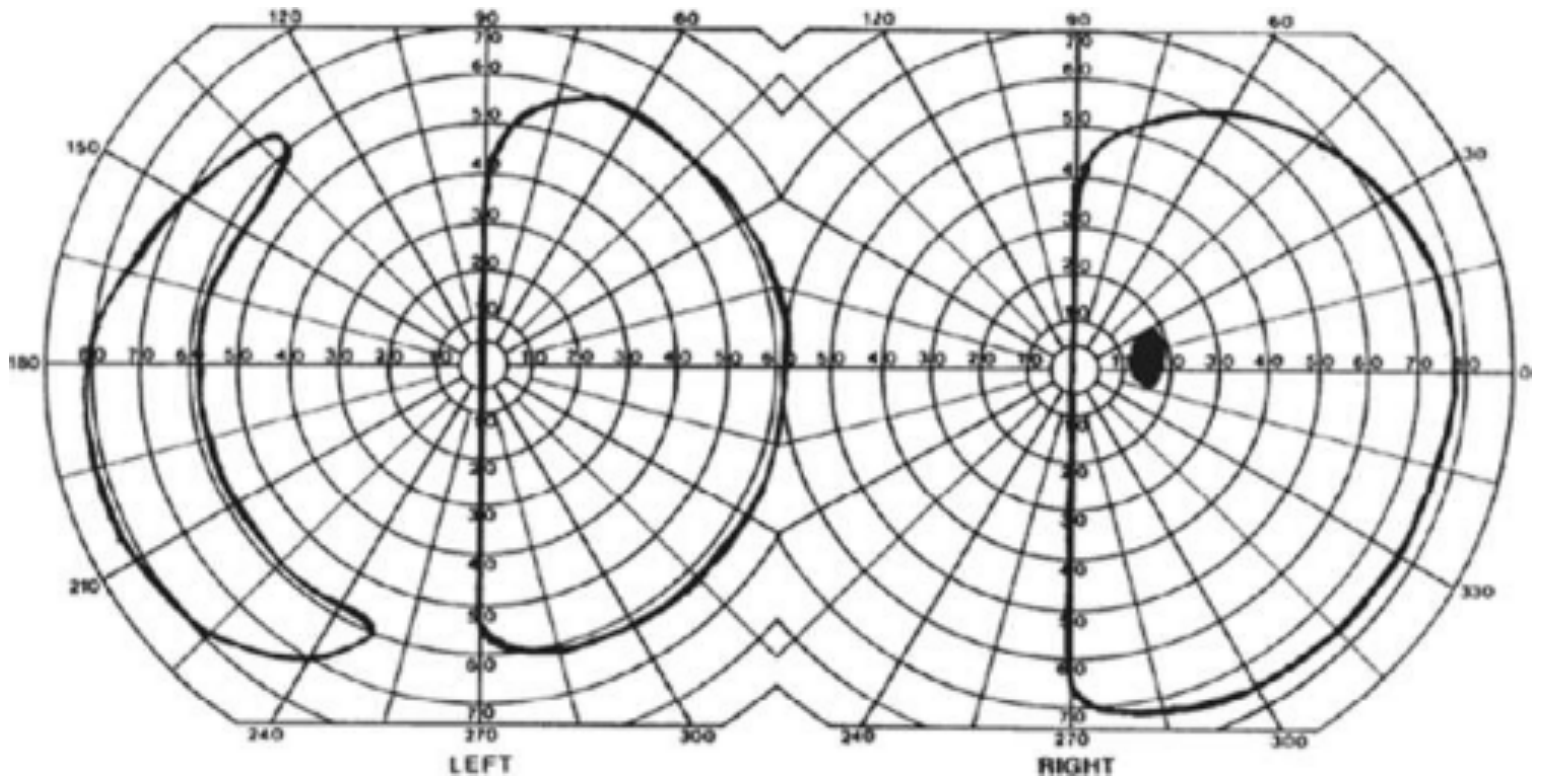
GHT
 Outside normal limits
 VFI: 66%
 MD: -16.06 dB P < 0.05
 PSD: 16.46 dB P < 0.05




© 2007 Carl Zeiss Meditec
 IFA 0 745-8508-4.2/4.2



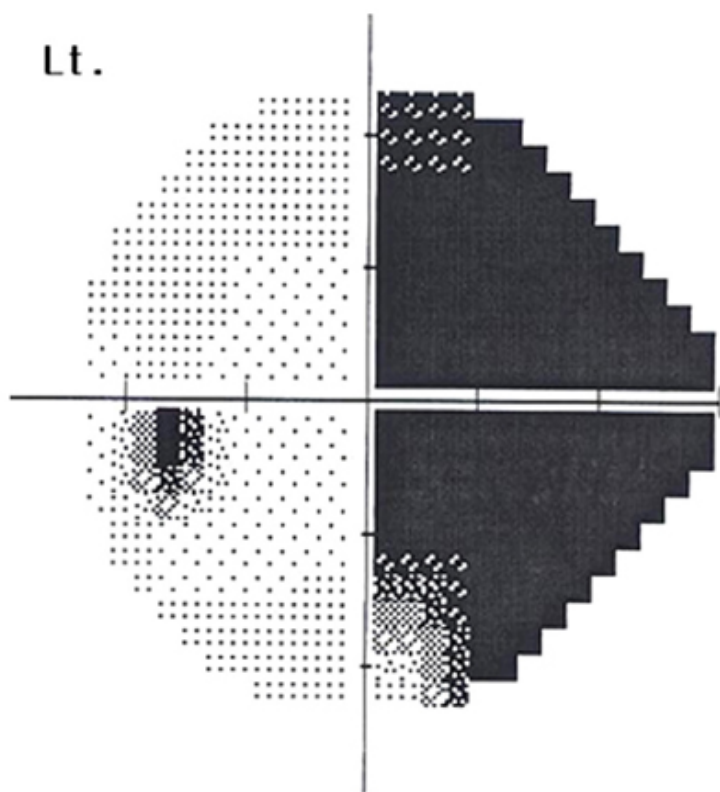
The normal visual field.



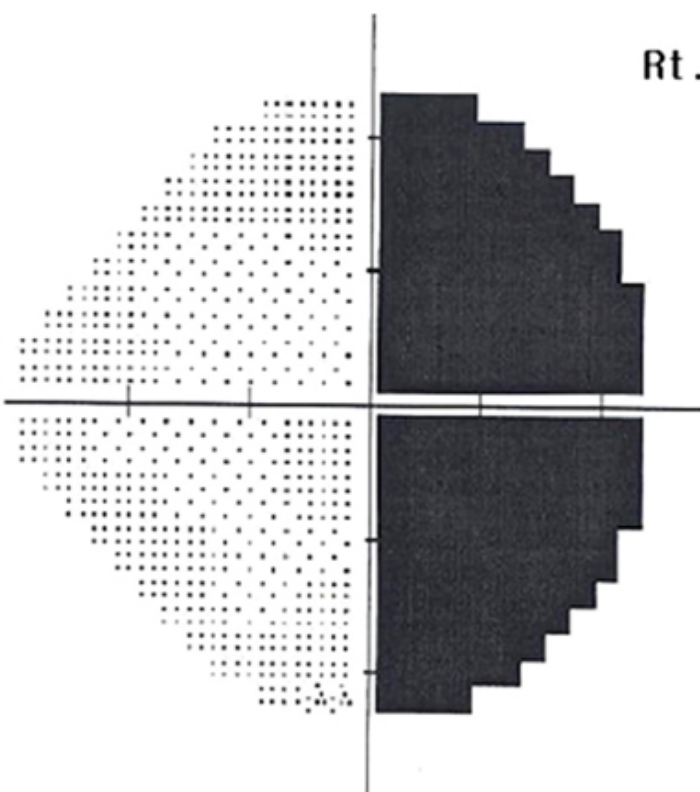
Who has the occipital stroke?



Lt.



Rt.



Beware juxtaposed homonymous VF loss

00

Single Field Analysis

Eye: Left

Name: TIBBETTS, DAVID
ID: 019653681

DOB: 04-11-1945

Central 24-2 Threshold Test


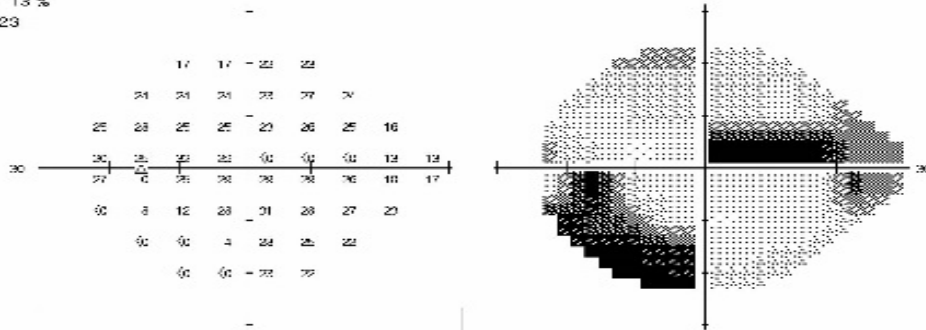
Fixation Monitor: Gaze/Blind Spot
Fixation Target: Central
Fixation Losses: 0/18
False POS Errors: 0 %
False NEG Errors: 13 %
Test Duration: 10:23

Stimulus: III, White
Background: 31.5 ASB
Strategy: SITA-Standard

Pupil Diameter: 4.4 mm
Visual Acuity:
RX: +3.25 DS DC X

Date: 05-08-2019
Time: 8:25 AM
Age: 74

Fovea: 33 dB



Total Deviation




Pattern Deviation

GHI
Outside Normal Limits



VFI 74%

MD -10.24 dB P < 0.5%

PSD 12.07 dB P < 0.5%



○ < 5%
⊘ < 2%
⊗ < 1%
● < 0.5%



TIBBETTS, DAVID
019653681
5/8/2019

© 2010 Carl Zeiss Meditec
HFA II 750-40252-5.1.1/5.1.1

Single Field Analysis

Eye: Right

Name: TIBBETTS, DAVID	DOB: 04-11-1945
ID: 019663681	

Central 24-2 Threshold Test

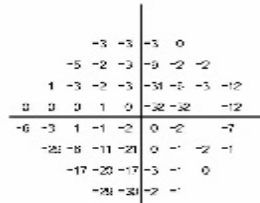
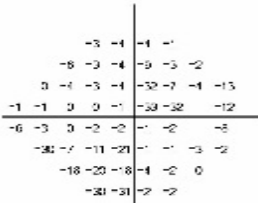
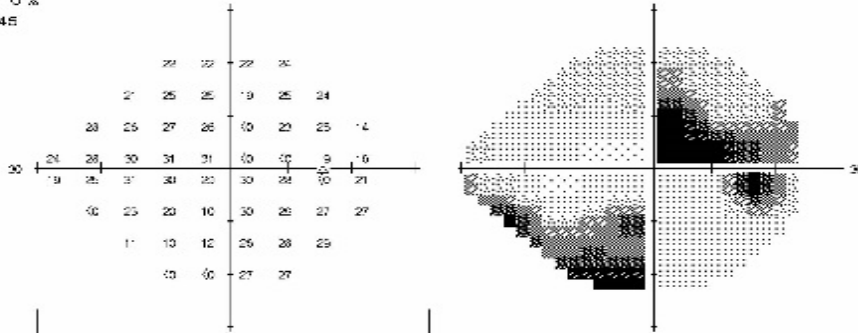
Fixation Monitor: Gaze/Blind Spot
 Fixation Target: Central
 Fixation Losses: 1/18
 False POS Errors: 3 %
 False NEG Errors: 0 %
 Test Duration: 08:45

Stimulus: III, White
 Background: 31.5 ABB
 Strategy: SITA-Standard

Pupil Diameter: 4.2 mm
 Visual Acuity:
 RX: +3.25 DS DC X

Date: 05-08-2019
 Time: 8:38 AM
 Age: 74

Fovea: 34 dB



GHT
 Outside Normal Limits

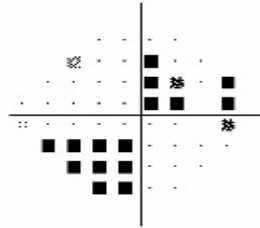
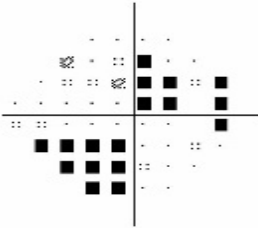
VFI 77%

MD -8.27 dB P < 0.5%


PSD 11.04 dB P < 0.5%

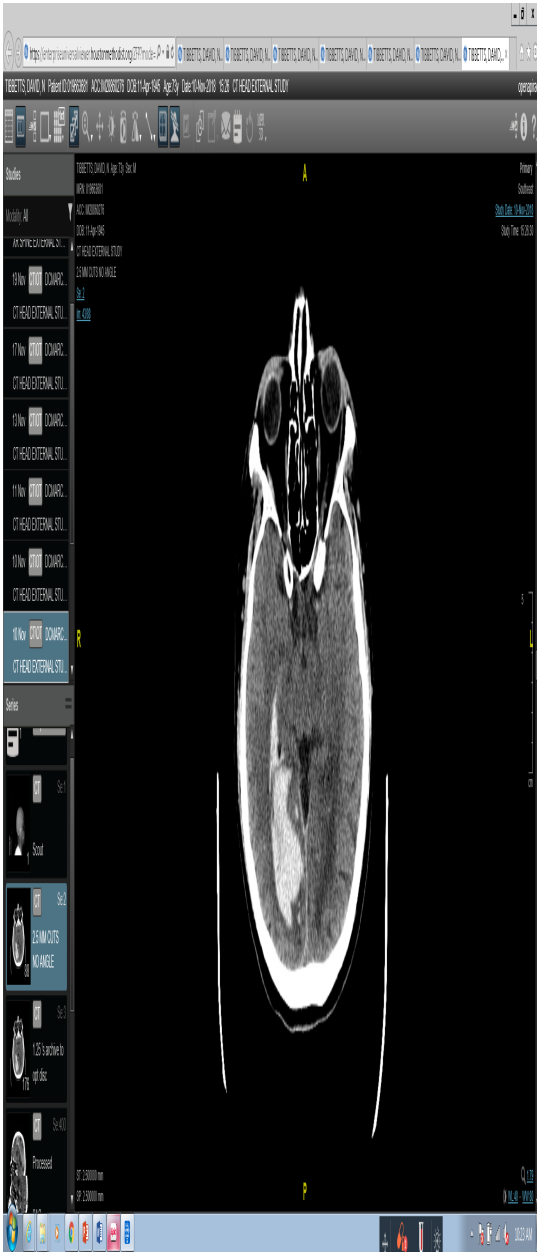Total Deviation

Pattern Deviation



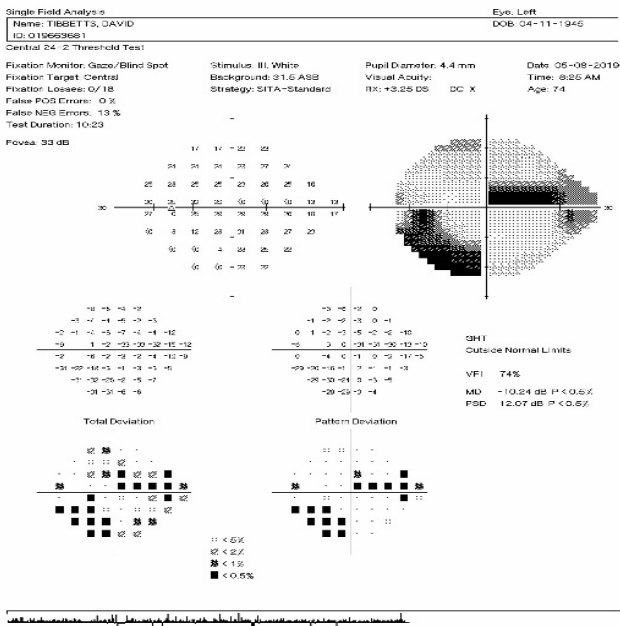
○ < 5%
 ◊ < 2%
 ◌ < 1%
 ■ < 0.5%





HOUSTON
Methodist
LEADING MEDICINE

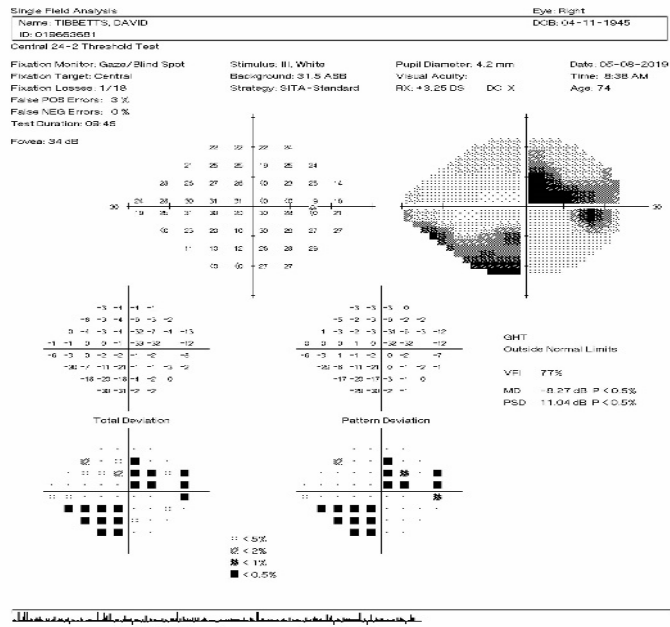
02



TIBBETTS, DAVID
018663681
5/8/2019

© 2010 Carl Zeiss Meditec
HFA II 750-40282-E.1.1/6.1.1

03



TIBBETTS, DAVID
018663681
5/8/2019

© 2010 Carl Zeiss Meditec
HFA II 750-40282-E.1.1/6.1.1

Summary: Five questions for visual field interpretation

Is it a one eye (unilateral) or two eye defect (bilateral)

If bilateral, horizontal or vertical step (bitemporal or homonymous)

Is it denser superiorly or inferiorly? Up is up and down is down (except lateral geniculate body): Pie in the sky: Temporal and Pie on the floor: Parietal


If homonymous, RAPD + band atrophy = optic tract lesion

If homonymous, is there congruity, a temporal crescent, macular sparing, or juxtaposed? = more likely to be occipital

On July 20, 1969, I was 5 years old, the moon landing was on tv....



“Houston” was the first word spoken from the moon



April 1970: “Houston, we’ve had a problem” — Jim Lovell



2-DISC ANNIVERSARY EDITION

TOM HANKS
A RON HOWARD FILM

APOLLO 13




"HOUSTON, WE HAVE A PROBLEM."


Jim Lovell



Half the spacecraft panel lost




Apollo fuel cell

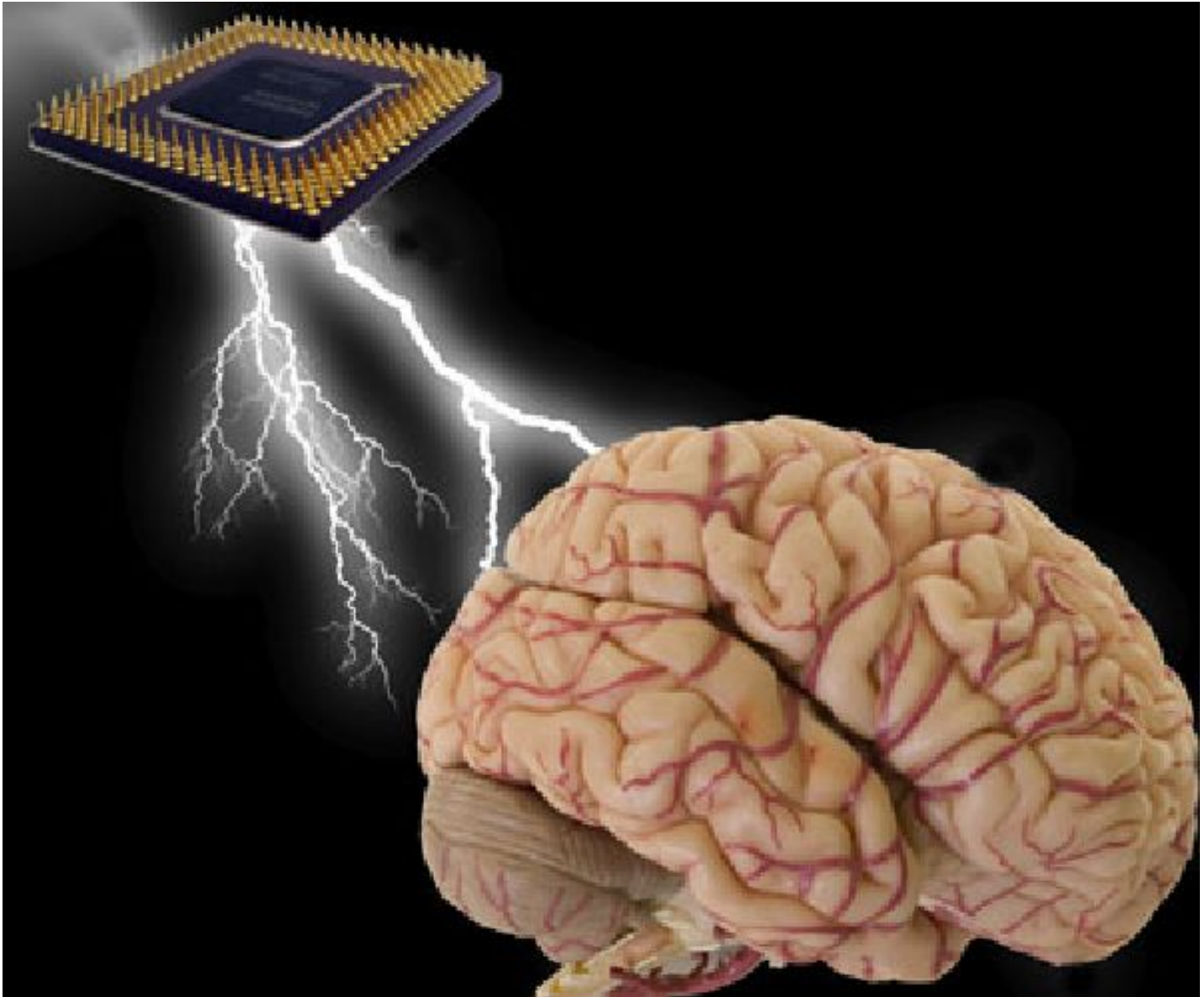




Most of the computing power was human brains at NASA

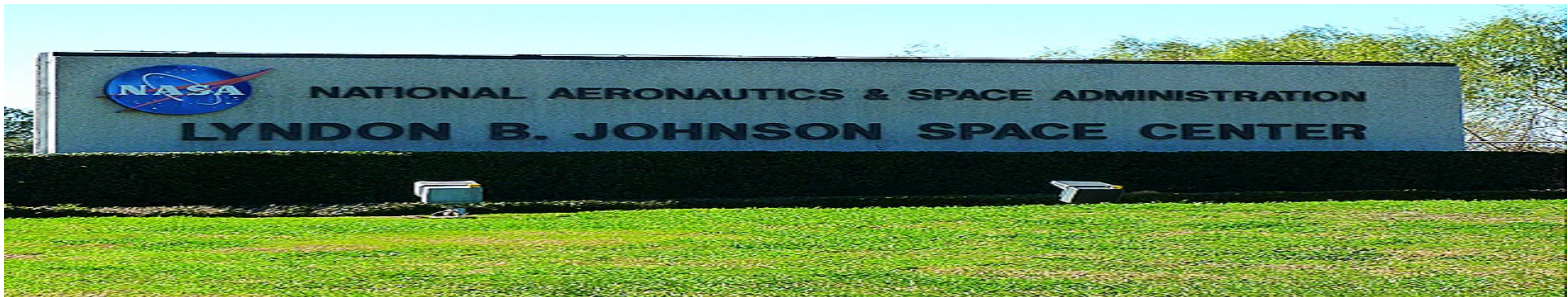

It was human brain power that brought
Apollo 13 home....

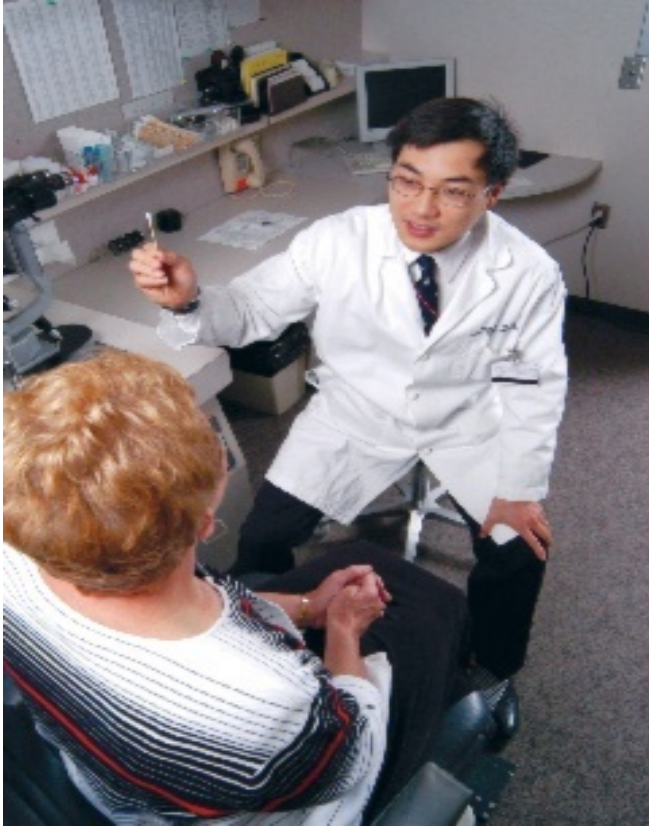



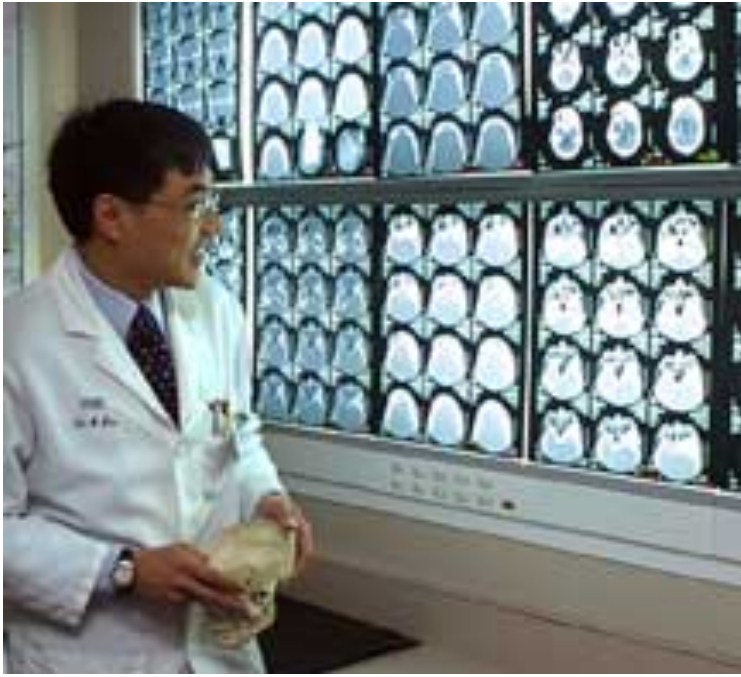JSC at NASA in Houston











1978: I wanted to be a doctor... 2nd NASA
& 3rd choice Jedi knight





It turns out I got to do all three...

Andrew G. Lee, MD

Houston, Texas

BCM

Baylor College of Medicine

THE UNIVERSITY OF TEXAS

MD Anderson
~~Cancer Center~~

Making Cancer History®

The logo for utmb Health, featuring the lowercase letters "utmb" in white on a red square background, followed by the word "Health" in a grey serif font.

Working together to work wonders.™



Weill Cornell Medical College

HOUSTON
Methodist[™]
TEXAS MEDICAL CENTER



TEXAS A&M
**HEALTH
SCIENCE
CENTER**
COLLEGE OF
MEDICINE

The logo of the University of Iowa Health Care, featuring a stylized graphic of a building or structure on the left. The text "UNIVERSITY of IOWA" is written in a serif font, with "of" in a smaller, italicized font. Below it, "HEALTH CARE" is written in a bold, sans-serif font.

UNIVERSITY
of IOWA
HEALTH CARE

